

A Systematic Review of Treatment of Cerebral Cavernous Malformations

Fathi Azwar S^{*1}, Muhammad Deni Nasution²

¹General Practitioner, Faculty of Medicine, University of North Sumatera, Medan, Indonesia

²Neurospine Surgeon, University of North Sumatera/Haji Adam Malik, Medan, Indonesia

*Corresponding Author: fathy_azwar@yahoo.com

ARTICLE INFO

Article history:

Received 3 February 2023

Revised 6 March 2023

Accepted 12 March 2023

Available online 29 April 2023

E-ISSN: 2686-0848

How to cite:

Syamlan FA, Nasution MD. A systematic review of treatment of cerebral cavernous malformations. Asian Australasian Neuro and Health Science Journal. 2023 Apr 05;01;15-23

ABSTRACT

Introduction: Cerebral cavernous malformations (CMs), also known as cavernomas, are brain vascular anomalies that consist of clusters of aberrant, hyalinized capillaries surrounded by hemosiderin deposits and a gliotic border. CMs are also known as cavernomas. The vasculature is filled with blood and can exhibit varying degrees of thrombosis. The familial form of CMs is inherited in an autosomal dominant manner and is caused by a heterozygous mutation in one of the three genes, CCM1, CCM2, and CCM3, which may be located on the 7q, 7p, and 3p chromosomes, respectively. This type of CMs affects only one member of the immediate family. Patients diagnosed with CMs make up anywhere from forty to sixty percent of those who have the familial variety. Treatment options for CM lesions include microsurgery, stereotactic radiosurgery, and conservative care. The most common procedure is called a microsurgical resection.

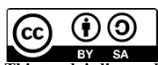
Method: The aim of study of this study to investigate the treatment of cerebral cavernous malformations. This study used the literature review method by discovering articles using the search engine PubMed and SagePub and 6 articles met the inclusion criteria in this study.

Result: According to the findings of the study, there were no significant variations in patient outcomes in terms of the frequency of seizures between those patients who had surgery and those who received conservative medicinal treatment.

Discussion: Cavernous malformations are intracerebral anomalies that were only brought to our attention in a meaningful way after the development of MRI technology. They are relatively frequent. Treatment includes microsurgery and radiosurgery. Microsurgery cures the patient but has substantial problems with complications, deterioration and partial removal. Cavernomas that were previously inoperable can now be treated with stereotactic radiosurgery. More research is required to fully understand the long-term neurological implications of SRS. In order to evaluate the efficacy of cavernoma treatments, the natural history of the tumors must be investigated.

Conclusion: Microsurgery, stereotactic radiosurgery, and conservative management treat CM lesions. Microsurgical resection is most common. Stereotactic radiosurgery can now treat inoperable cavernomas. SRS's long-term neurological effects need further study. The natural history of cavernomas must be studied to determine therapeutic success.

Keywords: Conservative, Cerebral cavernous malformations, Gamma knife radiosurgery, Microsurgery, Tumor



This work is licensed under a Creative Commons Attribution-ShareAlike 4.0 International.

DOI : 10.32734/aanhsj.v5i1.11247

1. Introduction

Cerebral cavernous malformations (CMs), also known as cavernomas, are brain vascular anomalies consisting of clusters of aberrant, hyalinized capillaries surrounded by hemosiderin deposits and a gliotic border. The vasculature is blood-filled and thrombosed to varied degrees.[1,2]. Cerebral CMs make up 10–25% of all vascular malformations, despite the fact that their frequency in the general population ranges from 0.4% to 0.8%. However, they are the most prevalent vascular anomaly. They are located all across the brain, but the majority, between 70 and 80 percent, are in the supratentorial region. [3].

The familial form of CMs is inherited in an autosomal dominant pattern and is caused by a heterozygous mutation in one of the three genes, CCM1, CCM2, and CCM3, which can be found on the 7q, 7p, and 3p chromosomes, respectively. Between forty and sixty percent of patients who have CMs have the familial form. [4,5].

The sporadic type of the disease normally only leads to a single cavernoma, in contrast to the familial form, which typically develops in several cavernomas. By forming associations with cytoskeletal and interendothelial cell junction proteins in neural tissue, it has been demonstrated that the products produced by the CM genes play a significant part in the process of angiogenesis. [5,6].

The endothelial cell-cell connections are disrupted when one of these genes is mutated in a way that causes it to lose its function. This results in severe vascular abnormalities and increased permeability. Microsurgical resection, stereotactic radiosurgery, and conservative maintenance are the three therapeutic options for CM lesions. Microsurgical resection is the most common. [1,7,8]. A necessary condition for successful surgical treatment is the selection of an appropriate surgical strategy that takes into account the diverse anatomical locations of the various CM lesions. In addition, damage to the normal peripheral brainstem tissues that surround CM lesions can result in substantial handicap; hence, the utilization of proper surgical procedures is of the utmost importance in situations like these. [9].

The correct surgical techniques not only resect the lesion, but they also reduce the risk of surgical harm and help assess the patient's prognosis once the lesion has been removed. [1,10]. The decision of how to treat a patient with CM is dependent on a wide variety of circumstances, all of which are covered in this article.

2. Method

This investigation's methodology was conducted in compliance with the Preferred Reporting Items for Systematic Review and Meta-Analysis (PRISMA) 2020 criteria. These elements influenced the decision to pass the legislation.

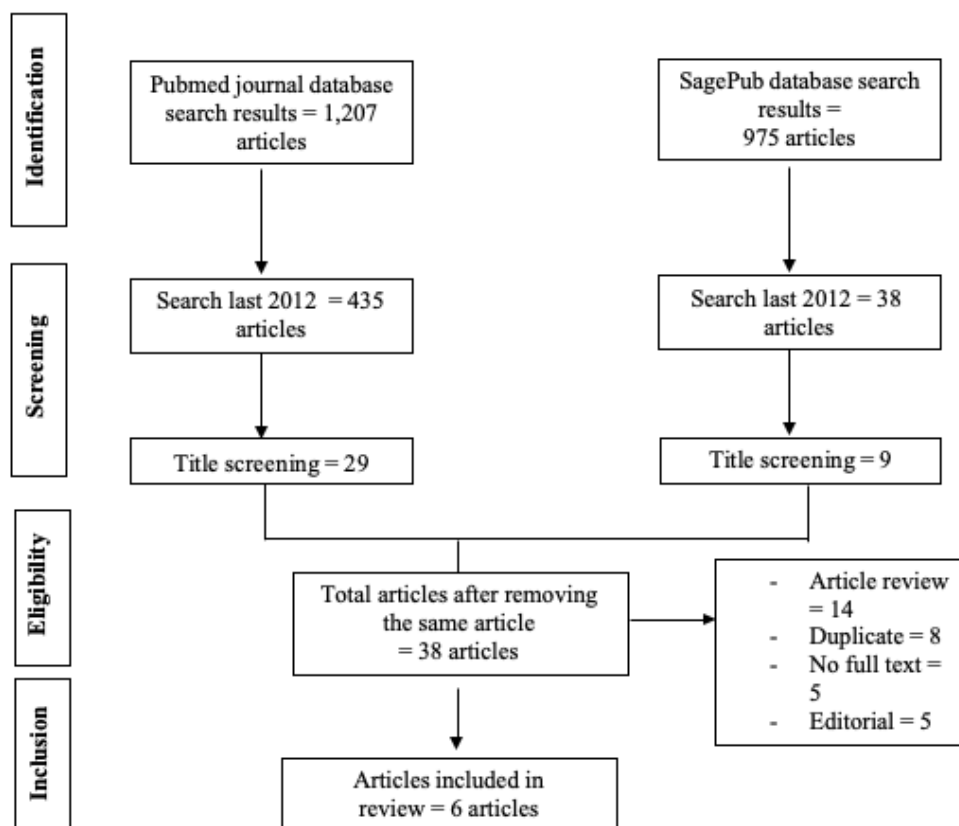


Fig. 1 Article search flowchart

Criteria for Eligibility

This literature review intends to explore the management of cerebral cavernous abnormalities by evaluating or analyzing prior research on the subject. This is a significant problem raised by the present investigation. Researchers participate in studies that satisfy the following requirements: 1) In order for publications to be considered for publication, they must be written in English and discuss about management of cerebral cavernous malformations. This assessment included articles published after 2012 but prior to the period covered by this systematic review. Examples include editorials, submissions without a DOI, already published review articles, and entries that are substantially similar to those previously published in a journal.

Search Strategy

The search for studies to be included in the systematic review using the PubMed and SagePub databases by inputting the words: “treatment” and “cerebral cavernous malformations” is used as search keywords.

Data retrieval

After completing a literature analysis that included an examination of the titles and abstracts of previously conducted research, the author changed the inclusion and exclusion criteria. The newly established criteria are explained in the supplemental materials for this study. This revealed the different facets of the issue that require additional examination, as well as its scope. The author arrived at this result after performing research on numerous other studies with a similar structure. During the process of conducting a systematic review, only papers that met all inclusion criteria were considered.

This ensured that only relevant information was discovered throughout the search. Thus, it was ensured that a comprehensive examination would be conducted. This endeavor revealed essential information about the studies, including their titles, authors, publication dates, locations, sorts of study activities, and parameters. These are the different widely available product categories. These are abilities that can be acquired via practice. Depending on the information source, this information may be presented in a variety of formats.

Quality Assessment and Data Synthesis

Before picking which publications to explore, the author independently researched a piece of research indicated in the titles and abstracts of the papers. Then, the complete texts of publications that match the inclusion criteria for the systematic review will be evaluated to determine which papers will be included in the review. This defines the articles that will be evaluated. To facilitate article selection for the review. Which studies meet the criteria for inclusion in the review.

3. Results

In the study that Gui et al. (2019) conducted, seven different surgical approaches were utilized. These included an orbitozygomatic approach (one case), a suboccipital transtentorial approach (Poppen approach; three cases), a subtemporal transtentorial approach (32 cases), a subtemporal transtentorial / anterior petrosectomy approach (9 cases), a suboccipital retrosigmoid approach (three cases), midline suboccipital approach (16 cases), and far lateral approach (3 cases). In every single one of the cases, a complete removal of the brainstem CM was accomplished. [8].

There was no fatality associated with the operation. After surgery, nine patients experienced new symptoms, including: three patients with diplopia, three patients with facial numbness, one patient with numbness of the contralateral limbs, one patient with transitory aphasia, and one patient with diminished muscle strength in the contralateral limbs. In 23 patients (34.3%), patients' symptoms greatly improved, while in 36 patients (53.7%), patients' symptoms remained the same, and in 9 patients (13.4%), patients experienced new postoperative problems. [8].

Table 1. The literature include in the study

Author	Origin	Method	Sample Size	Period	Therapy	Result
Gui, 2019[8].	China	Prospective study	67 patients (32 male, 35 female; average age 40 years; range, 14-68 years) with brainstem CMs	March 2011 and May 2013	Surgical	Gui, et al. (2019) conducted a study using seven surgical approaches: orbitozygomatic approach (1 case), suboccipital transtentorial approach (Poppen approach; 3 cases), subtemporal (32 cases), subtemporal / anterior petrosectomy (9 cases), retrosigmoid (3 cases), midline (16 cases), and far lateral (3 cases) (3 cases). All brainstem CMs were removed. No operative deaths occurred. After surgery, three patients suffered diplopia, three had facial numbness, one had contralateral limb numbness, one had transitory aphasia, and one had diminished muscle strength. 23 patients (34.3%) improved greatly, 36 (53.7%) remained stable, and 9 (13.4%) developed new postoperative problems.
Sommer, 2013[11].	Denmark	Prospective study	26 patients (14 female, 12 male, mean age 39.1 years, range: 17-63 years) with CM related epilepsy	September 2002 and March 2012	Surgical	All patients had complete CM removal verified by postsurgical MRI. As a direct result of iopMRI, refined surgery was required in 11.5% of patients to achieve total cavernoma excision and another 11.5% to achieve complete resection of additional surrounding epileptogenic brain. IopMRI confirmed the removal of the hemosiderin rim in 92% of individuals. Two individuals had mild (7.7%) visual field impairments and one had moderate (3.8%). With a mean follow-up duration of 47.7 months, 80.8% of patients obtained complete seizure control (Engel class 1A).
Fernandez, 2012[12].	Spain	Retrospective study	54 patients with cerebral cavernomas and epilepsy	No date	Surgical vs conservative	At two years, out of the 26 operated patients, 19 (73%) remained seizure free, 4 (15%) had less than a seizure per month, and one patient (4%) had more than one seizure per month. At five years, 15 patients of the surgical group remained for analysis. Of them, 11 (73.3%) were seizure free, and 4 (26.7%) had less than one seizure a month. In the medical group, 12 out of 17 patients were seizure free (70.6%). There were no significant differences between the two groups ($p = 0.2$ and $p = 0.3$, respectively). Seven patients had postoperative neurological sequelae.
Lee, 2014[13].	Korea	Retrospective study	49 patients with brainstem CMs	1992 to 2011	Gamma Knife radiosurgery (GKS)	In group A (GKS for a CM following a single symptomatic bleed), the annual hemorrhage rate (AHR) following GKS was 7.06 % within the

						first 2 years and 2.03 % after 2 years. In group B (GKS for a CM following two or more symptomatic bleeds), four patients (22.2 %) developed new or worsening neurologic deterioration as a result of repeat hemorrhages. In group B, the AHR was 38.36 % prior to GKS, 9.84 % within the first two years, and 1.50 % after two years. There was no statistically significant difference in the AHRs at each follow-up period after GKS between the two groups. Adverse radiation effects (AREs) developed in a total of four patients (8.2%); among them, one patient (2.0%) developed a permanent case of diplopia. No mortality occurred in this series.
Park, 2013[14].	Korea	Retrospective study	Twenty-one patients with symptomatic brainstem intra-axial CMs	2005 and 2010	Gamma Knife radiosurgery (GKS)	Before GKS, 31 patients had 1.55 hemorrhages. Pre- GKS bleeding rate was 39.5%. GKS revealed 1 hemorrhage (0.05 per patient). 6 months after radiosurgery. Steroids restored the patient to pre-morbid level. The first two years after GKS saw 8.2% yearly bleeding. No hemorrhages were found after latency. After radiosurgery, one patient (5%) developed permanent paresthesia without hemorrhage.
Moultrie, 2014[15]	United Kingdom	Prospective, population-based study	134 adults	1999-2003	Surgical or conservative management	25 underwent CCM excision; these adults were younger (34 vs 43 years at diagnosis, $p = 0.004$) and more likely to present with symptomatic intracranial hemorrhage or focal neurologic deficit than adults managed conservatively (48% vs 26%; odds ratio 2.7, 95% confidence interval [CI] 1.1-6.5). During 5 years of follow-up, CCM excision was associated with a deterioration to an Oxford Handicap Scale score 2-6 sustained over at least 2 successive years (adjusted hazard ratio [HR] 2.2, 95% CI 1.1-4.3) and the occurrence of symptomatic intracranial hemorrhage or new focal neurologic deficit (adjusted HR 3.6, 95% CI 1.3-10.0).

Sommer, et al (2013) study showed all patients had complete CM removal verified by postsurgical MRI. As a direct result of iopMRI, refined surgery was required in 11.5% of patients to achieve total cavernoma excision and another 11.5% to achieve complete resection of additional surrounding epileptogenic brain. IopMRI confirmed the removal of the hemosiderin rim in 92% of individuals. Two individuals had mild (7.7%) visual field impairments and one had moderate (3.8%). With a mean follow-up duration of 47,7 months, 80.8% of patients obtained complete seizure control (Engel class 1A).[11]

Fernandez, et al (2013) conducted a retrospective study with 43 patients non refractory epilepsy secondary. Twenty-six of them (60.5%) underwent surgery and made up the surgical group, and 17 patients were treated medically and constituted the medical group. Seizure frequency and other clinical variables were compared between both groups. They showed 19 (73%) remained seizure free, 4 (15%) had less than a seizure per month, and one patient (4%) had more than one seizure per month. At five years, 15 patients of the surgical group remained for analysis. Of them, 11 (73.3%) were seizure free, and 4 (26.7%) had less than one seizure a month. In the medical group, 12 out of 17 patients were seizure free (70.6%). There were no significant differences between the two groups ($p = 0.2$ and $p = 0.3$, respectively). Seven patients had postoperative neurological sequelae.[12]

Lee, et al (2014) showed patients underwent GKS for a CM following a single symptomatic bleed, the annual hemorrhage rate (AHR) following GKS was 7.06 % within the first 2 years and 2.03 % after 2 years. Patient underwent GKS for a CM following two or more symptomatic bleeds), four patients (22.2%) developed

new or worsening neurologic deterioration as a result of repeat hemorrhages. In group B, the AHR was 38.36 % prior to GKS, 9.84 % within the first two years, and 1.50 % after two years. There was no statistically significant difference in the AHRs at each follow-up period after GKS between the two groups. Adverse radiation effects (AREs) developed in a total of four patients (8.2%); among them, one patient (2.0%) developed a permanent case of diplopia. No mortality occurred in this series.[13]

Park, et al (2013) showed 31 hemorrhages found before GKS, which averaged out to 1.55 per patient. Before the implementation of GKS, the annual bleeding rate was 39.5% (when accounting for the initial hemorrhage). Following GKS, one hemorrhage was discovered, which equates to 0.05 per patient. It happened six months after the radiosurgery was performed. After GKS, the annual bleeding rate was 8.2% for the first two years after the procedure.[14]

After the period of latency that was anticipated, there was no sign of any hemorrhaging. After the radiosurgery, one patient, which accounts for five percent of the total, displayed permanent paresthesia. This was a novel neurologic symptom that occurred in the absence of any hemorrhagic episode.

Last study with 25 underwent CCM excision; these adults were younger (34 vs 43 years at diagnosis, $p = 0.004$) and more likely to present with symptomatic intracranial hemorrhage or focal neurologic deficit than adults managed conservatively (48% vs 26%; odds ratio 2.7, 95% confidence interval [CI] 1.1-6.5). During 5 years of follow-up, CCM excision was associated with a deterioration to an Oxford Handicap Scale score 2-6 sustained over at least 2 successive years (adjusted hazard ratio [HR] 2.2, 95% CI 1.1- 4.3) and the occurrence of symptomatic intracranial hemorrhage or new focal neurologic deficit (adjusted HR 3.6, 95% CI 1.3-10.0). [15].

4. Discussion

Cerebral cavernous malformations, also known as CCMs, are a particular form of vascular lesion that manifest themselves only in the central nervous system. CCMs are not a major underlying cause of cerebrovascular disease; yet, research into them has been extraordinarily fruitful and has revealed surprising molecular and genetic insight into the development of vessels and diseases that affect them. [16]. In spite of the fact that bleeding is a major cause of morbidity in CCM, the molecular and cellular mechanisms that drive acute or chronic hemorrhage in this disease are not well understood. CCMs are characterized by their dynamic nature, as they are able to develop, grow, shrink, or behave aggressively, all while causing recurrent hemorrhaging. [17].

Cavernous malformations are intracerebral anomalies that were only brought to our attention in a meaningful way after the development of MRI technology. They are relatively frequent. [1,18]. Treatment includes microsurgery and radiosurgery. Microsurgery cures the patient but has substantial problems with complications, deterioration and partial removal. A meta-analysis conducted by Bubenikova and colleagues in 2022 demonstrated that surgical resection of CCM is effective in ensuring the prevention of hemorrhage with acceptable morbidity and mortality; nevertheless, conservative and radiosurgical care is a justifiable treatment alternative. The majority of CCMs that affect the brainstem and those that are deeply seated are linked to greater bleeding rates. [19].

The surgical indications were defined by the notion that the danger and severity of rehemorrhage-induced neurologic damage outweighed the risk and severity of surgery-induced neurologic damage. As a result, study recommend just monitoring and follow-up for patients who experienced a first bleed with lesions <1 cm in diameter and positioned relatively far from the brainstem surface. However, if a patient has a history of hemorrhage and presents with evident symptoms, and the lesion is >2 cm in diameter and located on the surface of the brainstem, surgical resection is recommended. [20].

Bleeding of the CM inside the medulla can result in death, so surgical reasons for patients with medullary CM should be modified. According to the research, surgery should be performed between 3 weeks to 1 month of a hemorrhage for the following reasons. [20]. First, based on our observations, a portion of the hematoma can liquefy during this time period, and a gliosis can form around the lesion, both of which will aid in the isolation of lesions from peripheral brainstem tissues. During this time, the lesion will be lightly linked to the peripheral brainstem tissues, making resection easier and reducing surgical harm. [3,11].

Some patients in with delayed diagnosis or waited a long time for surgery (3-6 months after hemorrhage), and patients with solidified hematomas that were firmly adhered to the peripheral brainstem tissues, which increased surgical difficulty and led to more surgical injury. Second, MRI can clearly detect hematomas and lesions during this time period. The specified location of lesions within the hematoma is critical in determining the best surgical technique. Furthermore, they feel that hemiplegia, disturbed consciousness, and inadequate breath or heart rate are not surgical contraindications. [20].

In contrast, the occurrence of these symptoms indicates that surgery should be undertaken as soon as feasible to prevent future neurologic damage. In this study, four patients experienced varied degrees of consciousness disruption (drowsiness or light coma), but after surgery and supportive care, they all gradually regained consciousness. Patients with lesions located inside the medulla who exhibit clear symptoms should have surgery considered as soon as possible, as these lesions can induce abnormalities in breath and heart rate, which can end in abrupt death. [20].

When the lesion reaches the brainstem's surface, it generates a natural pathway to the lesion. To avoid damage to critical structures in the event of a lesion that does not reach the surface, safe entry zones are established. Because the nuclei and corticospinal fibers are mostly found in the dorsal and ventral brainstems, they frequently adopt lateral methods.

Brown et al. proposed a two-point system for selecting the best approach to brainstem lesions: the first point represents the lesion's center, and the second point represents the spot closest to the brainstem surface or the site deemed safe for brainstem incision. [21].

The pointed place on the skull surface would be the best location for the craniotomy if the two points were connected and the line was extended outward. However, in actual clinical practice, many other factors, such as clinical manifestations, site of lesion, location of lesion closest to brainstem surface, peripheral brainstem function, type and distribution of hematoma, accompanying veins, surgeon's familiarity with different approaches, and individual patient condition, must be considered when determining a proper approach. [15,22].

In other hand, Fernandez et al (2012) showed no significant differences in patient outcomes in terms of seizure frequency between those who underwent surgery and those who received conservative medicinal treatment ($p = 0.2$ and $p = 0.3$, respectively). In patients with multiple cavernomas, they found comparable effects. However, the surgical patients had a higher chance of successfully discontinuing antiepileptic medication than the medically treated patients (32-34% vs. 14%, respectively). Surgery in patients with new-onset epilepsy, random seizures, or non-well-established refractory epilepsy should be planned with caution, because seizure frequency would likely be the same if the patient had medication treatment instead.

Other study showed GKS was determined to be a safe and effective treatment modality for decreasing recurrent hemorrhage in brainstem CMs. The AHRs of the within-two-years and beyond-two-years post-GKS patients in group underwent GKS for a CM following a single symptomatic bleed are compatible with the AHRs of group underwent GKS for a CM following two or more symptomatic bleeds. Among the four patients (8.2%) who experienced AREs, only one patient (2.0 %) was left with a permanent deficit of diplopia. They therefore suggest that patients with CMs that have bled even once could be considered for GKS rather than for observation when the lesion is located in a surgically inaccessible area. [13,14].

In the past twenty years, stereotactic radiosurgery, also known as SRS, has emerged as a viable alternative to the more traditional method of surgical care for high-risk CMs that are located in the brainstem. A high degree of accuracy and a rapid radiation dose fall-off at the periphery of target lesions can be provided by stereotactic radiosurgery. This enables the doctor to apply a high radiation dosage to CMs while sparing healthy brain tissue. The incidence of radiation-induced complications following SRS for CMs is significantly higher than the incidence of radiation-induced complications following SRS for AVMs in equivalent doses and similar locations. [23].

5. Conclusion

Microsurgery, stereotactic radiosurgery, and conservative management treat CM lesions. Microsurgical resection is most common. Stereotactic radiosurgery can now treat inoperable cavernomas.

SRS's long-term neurological effects need further study. The natural history of cavernomas must be studied to determine therapeutic success.

Acknowledgements

None.

Conflict of Interest

The authors declare no conflicts of interest in preparing this article.

References

- [1] Dalyai RT, Ghobrial G, Awad I, Tjounmakaris S, Gonzalez LF, Dumont AS, et al. Management of incidental cavernous malformations: a review. *Neurosurg Focus*. 2011;31(6):E5.
- [2] Raychaudhuri R, Batjer HH, Awad IA. Intracranial cavernous angioma: a practical review of clinical and biological aspects. *Surg Neurol*. 2005;63(4):319–28.
- [3] Mouchtouris N, Chalouhi N, Chitale A, Starke RM, Tjounmakaris SI, Rosenwasser RH, et al. Management of cerebral cavernous malformations: from diagnosis to treatment. *Sci World J*. 2015;2015.
- [4] D'Angelo VA, De Bonis C, Amoroso R, Cali A, D'Agruma L, Guarnieri V, et al. Supratentorial cerebral cavernous malformations: clinical, surgical, and genetic involvement. *Neurosurg Focus*. 2006;21(1):1-7.
- [5] Wang C, Liu A, Zhang J, Sun B, Zhao Y. Surgical management of brain-stem cavernous malformations: report of 137 cases. *Surg Neurol*. 2003;59(6):444–54.
- [6] Huang AP-H, Chen J-S, Yang C-C, Wang K-C, Yang S-H, Lai D-M, et al. Brain stem cavernous malformations. *J Clin Neurosci*. 2010;17(1):74–9.
- [7] Garrett M, Spetzler RF. Surgical treatment of brainstem cavernous malformations. *Surg Neurol*. 2009;72:S3–9.
- [8] Gui S, Meng G, Xiao X, Wu Z, Zhang J. Surgical management of brainstem cavernous malformation: report of 67 patients. *World Neurosurg*. 2019;122:e1162–71.
- [9] Gross BA, Lin N, Du R, Day AL. The natural history of intracranial cavernous malformations. *Neurosurg Focus*. 2011;30(6):E24.
- [10] Ganz JC. Chapter 8 - Cavernous malformations. In: Ganz JC BT-P in BR, editor. *Recent Advances and Controversies in Gamma Knife Neurosurgery* [Internet]. Elsevier; 2022. p. 115–32. Available from: <https://www.sciencedirect.com/science/article/pii/S0079612321002284>
- [11] Sommer B, Kasper BS, Coras R, Blumcke I, Hamer HM, Buchfelder M, et al. Surgical management of epilepsy due to cerebral cavernomas using neuronavigation and intraoperative MR imaging. *Neurol Res*. 2013;35(10):1076–83.
- [12] Fernández S, Miró J, Falip M, Coello A, Plans G, Castañer S, et al. Surgical versus conservative treatment in patients with cerebral cavernomas and non refractory epilepsy. *Seizure*. 2012;21(10):785–8.
- [13] Lee SH, Choi HJ, Shin HS, Choi SK, Oh IH, Lim YJ. Gamma Knife radiosurgery for brainstem cavernous malformations: should a patient wait for the rebleed? *Acta Neurochir (Wien)*. 2014 Oct;156(10):1937–46.
- [14] Park S-H, Hwang S-K. Gamma knife radiosurgery for symptomatic brainstem intra-axial cavernous malformations. *World Neurosurg*. 2013 Dec;80(6):e261-6.
- [15] Moultrie F, Horne MA, Josephson CB, Hall JM, Counsell CE, Bhattacharya JJ, et al. Outcome after surgical or conservative management of cerebral cavernous malformations. *Neurology*. 2014 Aug;83(7):582–9.
- [16] Snellings DA, Hong CC, Ren AA, Lopez-Ramirez MA, Girard R, Srinath A, et al. Cerebral Cavernous Malformation: From Mechanism to Therapy. *Circ Res*. 2021 Jun;129(1):195–215.
- [17] Goldberg J, Jaeggi C, Schoeni D, Mordasini P, Raabe A, Bervini D. Bleeding risk of cerebral cavernous malformations in patients on β -blocker medication: a cohort study. *J Neurosurg*. 2018;130(6):1931–6.
- [18] Ganz JC. Cavernous malformations. *Prog Brain Res*. 2022;268(1):115–32.

- [19] Bubenikova A, Skalicky P, Benes VJ, Benes VS, Bradac O. Overview of cerebral cavernous malformations: comparison of treatment approaches. *J Neurol Neurosurg Psychiatry*. 2022 May;93(5):475–80.
- [20] Chen L, Zhao Y, Zhou L, Zhu W, Pan Z, Mao Y. Surgical strategies in treating brainstem cavernous malformations. *Neurosurgery*. 2011 Mar;68(3):601–9.
- [21] Brown AP. The two-point method: evaluating brain stem lesions. *BNI Q*. 1996;12:20–4.
- [22] Giliberto G, Lanzino DJ, Diehn FE, Factor D, Flemming KD, Lanzino G. Brainstem cavernous malformations: anatomical, clinical, and surgical considerations. *Neurosurg Focus*. 2010 Sep;29(3):E9.
- [23] Lu X-Y, Sun H, Xu J-G, Li Q-Y. Stereotactic radiosurgery of brainstem cavernous malformations: a systematic review and meta-analysis. *J Neurosurg*. 2014 Apr;120(4):982–7.