

Comparative between Syndromic and Non Syndromic Craniosynostosis: A Literature Review

Muhammad Fahmi Rasyid¹, Abdurrahman Mouza²

¹Faculty of Medicine, Universitas Sumatera Utara, Indonesia

²Department of Neurosurgery, Universitas Sumatera Utara, Medan, Indonesia

Abstract

Craniosynostosis (CS) refers to the premature fusion in the perinatal stage of one or multiple skull sutures, also denominated synostoses (sagittal, metopic, uni and bilateral coronal, and lamboidal), which are commonly accompanied by facial, trunk, and limb deformities. During normal human body and head development, cranial growth achieves approximately 80% of the adult size at birth and its definitive size between 2.5 and 3 years of age. In the fetal or newborn skull, the flat bones are separated by four fontanelles and six major cranial sutures that participate in this process. Hereby presented the literature review of syndromic and non-syndromic craniosynostosis.

Keyword: syndromic, non-syndromic, craniosynostosis

Introduction

Craniosynostosis is defined as the premature fusion of one or more cranial sutures. According to Virchow's concept, fusion of a cranial vault suture restricts growth perpendicular to it but "extra" growth parallel to produce an often typical skull deformity. More recent theories invoke the action of a "functional matrix" that comprises not only bone, but also the adjacent dura and other soft tissues.¹

The incidence of CS has been estimated at 1 per 2,000-2,500 live newborns, thus comprising the second most common craniofacial disorder after orofacial clefts.² Craniosynostosis occurs in 1 in 2100 to 1 in 2500 births and may be either nonsyndromic (also referred to as isolated) or syndromic. In syndromic craniosynostosis, other birth defects are present next to the craniosynostosis. In syndromic craniosynostosis, usually more than 1 cranial sutures have prematurely fused, typically involving both coronal sutures.³

Sutures	Beginning of fusion
Metopic	2 months
Sagittal	22 months
Coronal	24 months
Lambdoid	26 months
Frontonasal	68 months
Frontosphenoidal	22 months
Temporal squamosal	35-39 months

Figure 1. Major and secondary skull sutures and age at the onset of fusion¹

*Corresponding author at: Faculty of Medicine, Universitas Sumatera Utara, Medan, Indonesia

Craniosynostosis is a congenital cranial malformation in which 1 or more cranial sutures have fused already in utero. The cranial sutures separate the skull bone plates and enable rapid growth of the skull in the first 2 years of life, in which growth is largely dictated by the growth of the brain.⁴

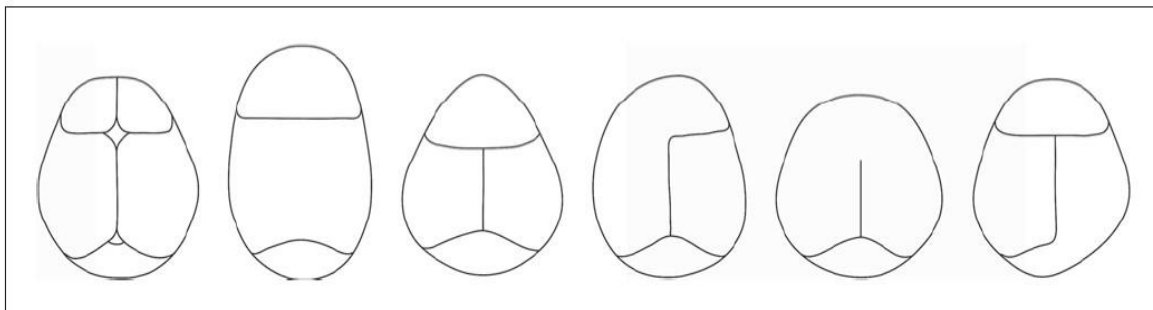


Figure 2. Craniosynostosis. From left to right: normal calvarial sutures, sagittal suture synostosis leading to a scaphocephalic head shape, metopic suture synostosis leading to trigonocephaly, left coronal suture synostosis leading to left-sided plagiocephaly, bicoronal suture synostosis leading to a brachycephalic head shape, and right lambdoid suture synostosis leading to right-sided occipital plagiocephaly.^{2,9}

Sagittal synostosis:	frontal bossing, prominent occiput, bone ridge palpable on sagittal suture, decreased biparietal diameter, long and narrow head, tapering from parietal to sagittal suture, with usually a head circumference >2 SD. ^{1,5,6,8}
Metopic synostosis:	wedge-shaped forehead, including cranial part of the orbits, ridge on metopic suture, and hypotelorism. ^{5,12}
Unicoronal synostosis:	flattened forehead at afflicted side, including flattening of cranial part of the orbits, flattened cheek, nose deviation to unaffected side, orbital dystopia with higher position of the ipsilateral orbital rim, and bossing of contralateral side of forehead. ⁵
Lambdoid synostosis:	unilateral occipital flattening, depression of lambdoid suture ridge, low-positioned ipsilateral ear and back of the skull base. ⁵
Bicoronal synostosis:	broad head, flattened forehead and supraorbital rim. ⁵

Figure 3. More in detail the different craniosynostoses of Physical Examination of Skull and Face⁴

Secondly, on the basis of etiology, craniosynostoses are divided into either primary or secondary subtypes. Primary craniosynostosis, the most common type, occurs in isolation. This is contrasted with secondary craniosynostosis where suture fusion is associated with another disorder such as thalassemia, hyperthyroidism, hematologic and metabolic disorders. Finally, craniosynostosis can be either nonsyndromic (isolated) or syndromic.⁶

Type	Suture	Syndromic	Name
Primary	Single suture	Non-syndromic	Scaphocephaly
		Non-syndromics	Plagiocephaly
			Trigonocephaly
			Brachycephaly
			Oxycephaly
	Multiple sutures	Syndromics	Crouzon
			Apert
			Pfeiffer
			Saethre- Chotzen
Secondary	To storage disorders of mucopolysaccharides		Hurler
			Morquio
	To metabolic disorders		rickets
			Hypothyroidism
	To hematological disorders		Polycythemia vera
			Thalassemia
	To medication intake		Retinoic acid
			Diphenylhydantoin

Figure 4. Thompson and Hayward classification of craniosynostosis.¹⁰

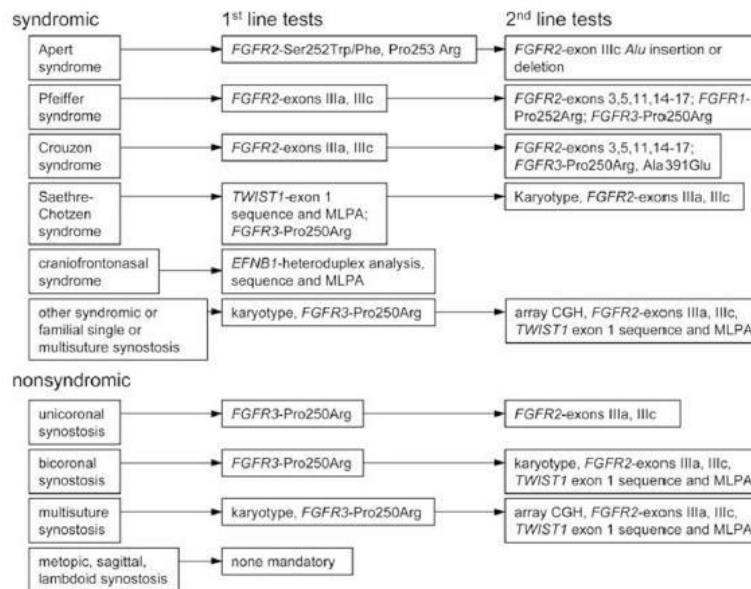


Figure 5. Flow diagram for molecular genetic diagnosis of craniosynostosis, showing the minimum tests recommended for each clinical presentation. In practice, the Oxford laboratory bundles sequencing of the FGFR1, FGFR2 (exons IIIa and IIIc), FGFR3 and TWIST1 genes together into a single ‘level 1’ screen to simplify the workflow.²⁰

2. Non-Syndromic Craniosynostosis

2.1 Incidence

Approximately 80% of the cases belong to the NSCS group. CS occurs more commonly overall in boys than in girls.² Nonsyndromic craniosynostosis is more commonly encountered than syndromic cases in pediatric craniofacial surgery.⁵

2.2 Classification

In nonsyndromic or isolated craniosynostosis, there are no other evident abnormalities other than those associated with early sutural fusion, such as neurological or ophthalmologic manifestations and there are different types on the basis of the fused suture, as scaphocephaly, brachycephaly, trigonocephaly and plagiocephaly.⁶

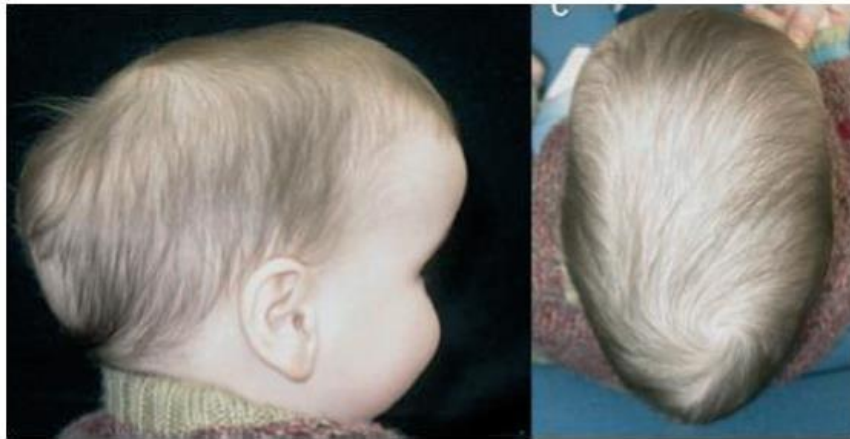

Figure 6. Scaphocephaly.⁶

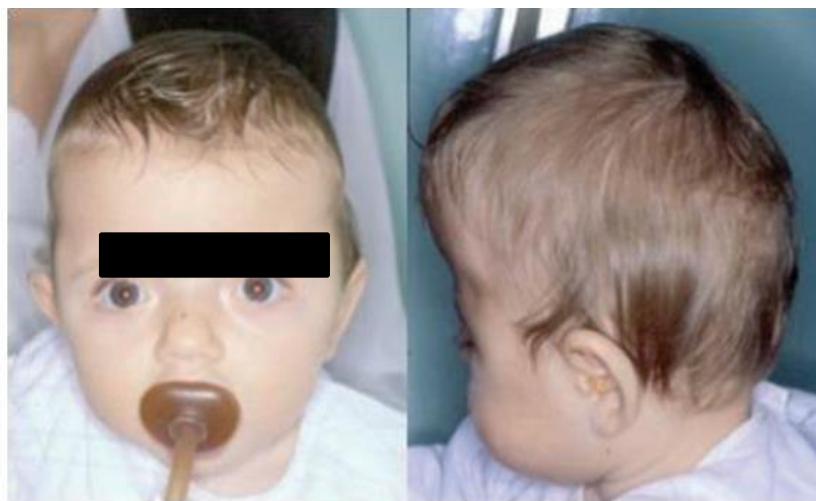

Figure 7. Brachycephaly.⁶

Trigonocephaly is associated with metopic synostosis and arrowing of the anterior calvaria. There is usually a prominent mid-frontal ridge (pointed forehead) down the forehead that can be seen or felt, and the eyebrows may appear ‘pinched’ on either side.⁶

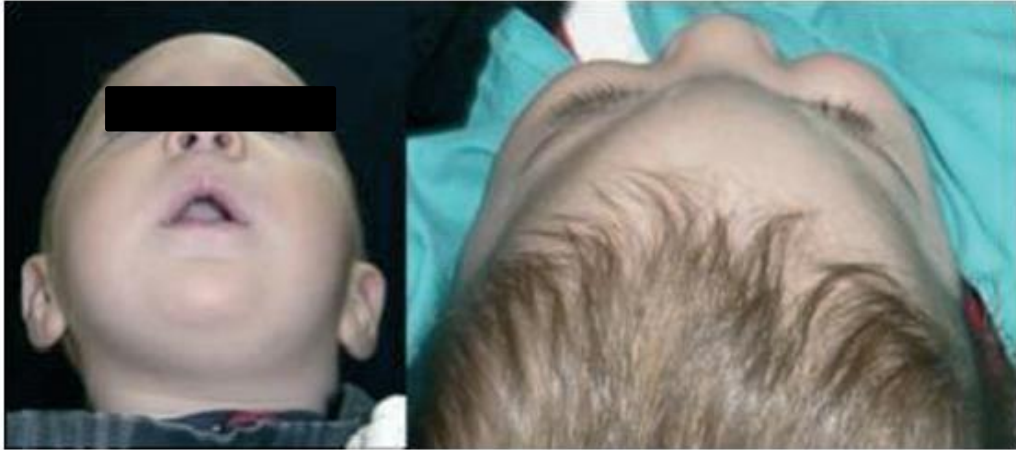

Figure 8. Trigonocephaly.⁶

Plagiocephaly results from unilateral coronal synostosis, with a recessed forehead and fronto-orbital rim and contralateral bossing of the forehead and fronto-orbital rim.⁶

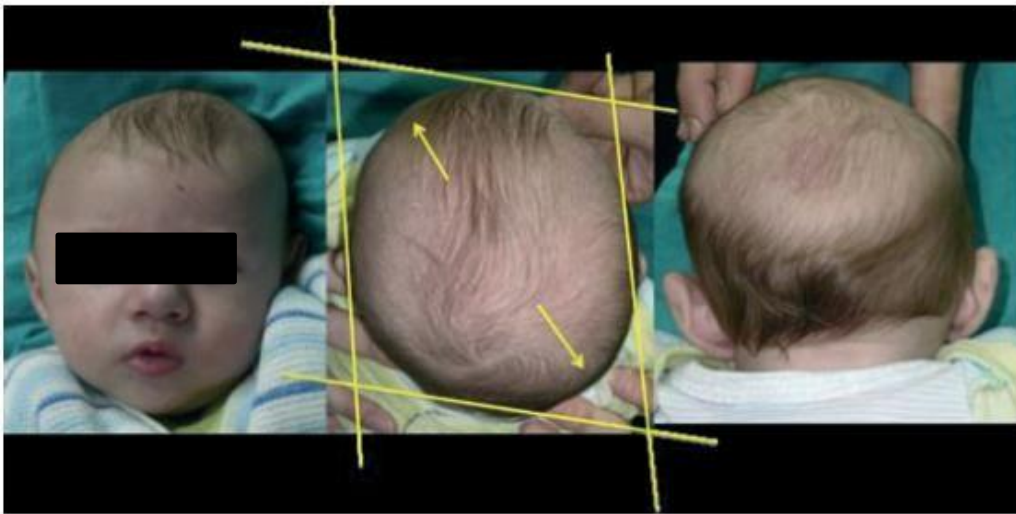

Figure 9. Posterior deformational plagiocephaly.⁶

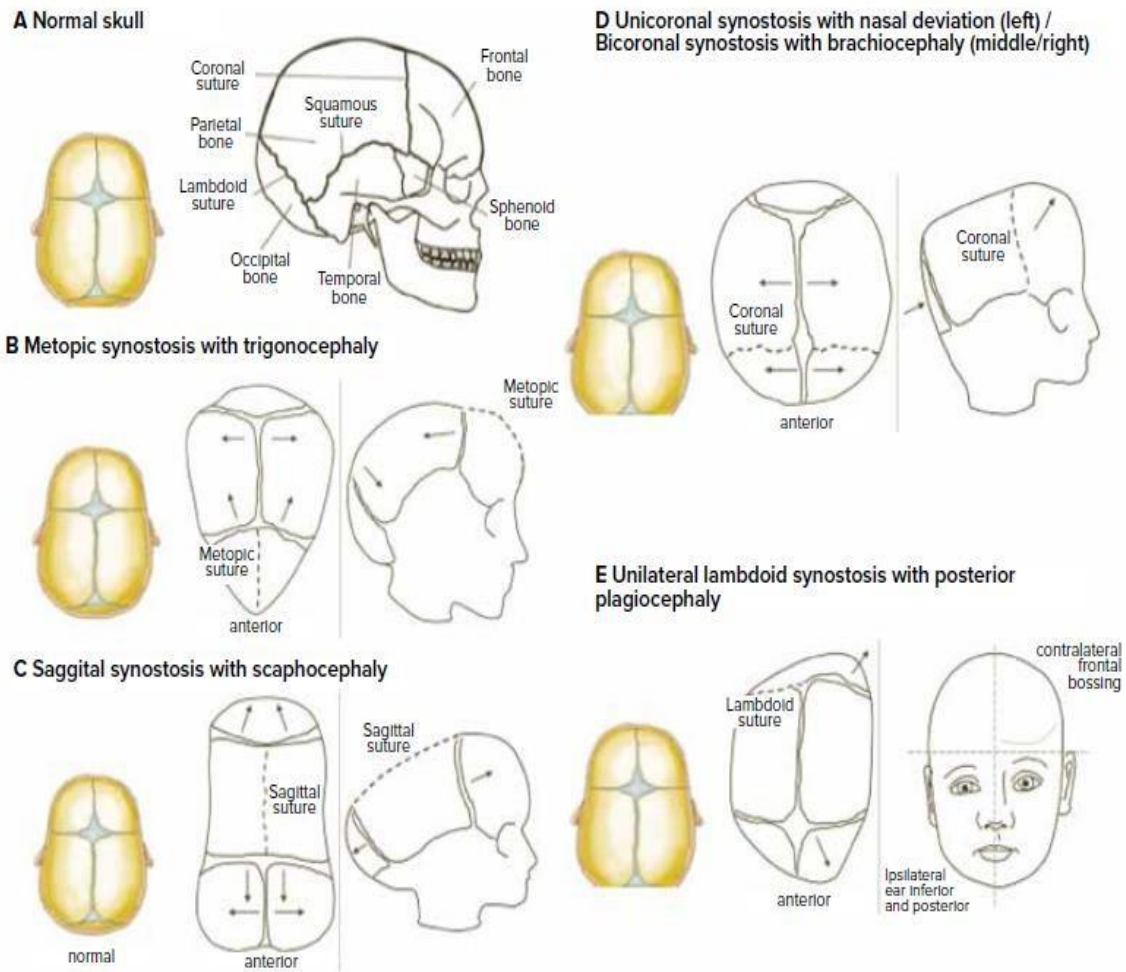


Figure 10. Cranial sutures and deformity of single suture craniosynostosis. With permission from Senarath-Yapa.

Sagittal synostosis is the most common form of craniosynostosis and comprises 45% of nonsyndromic cases. Sagittal suture fusion results in a boat-shaped deformity of the skull, termed scaphocephaly, with growth restriction in width and compensatory excessive growth in calvarial length in the anterior to posterior direction.⁵

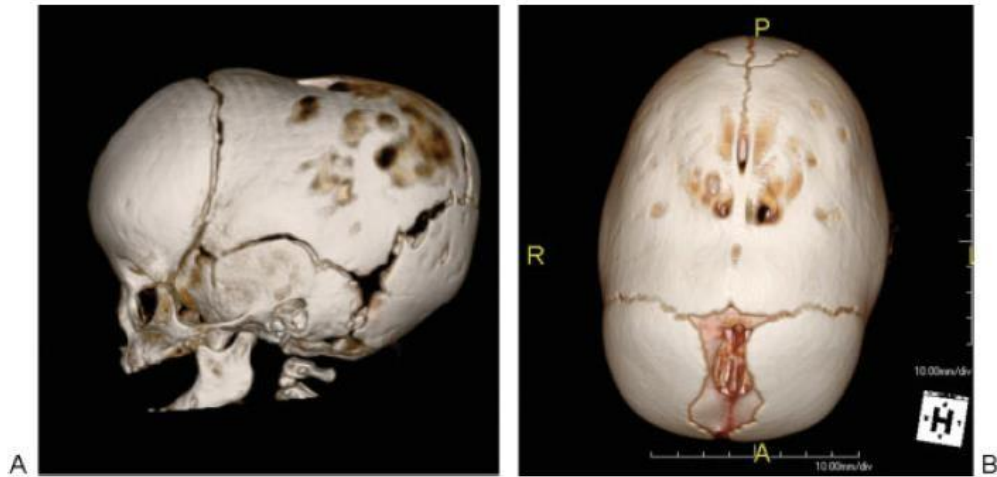


Figure 11. Three-dimensional computed tomography reconstructions of sagittal synostosis. (A) Lateral view demonstrating scaphocephaly and saddle deformity of the skull. (B) Vertex view (forehead is oriented downward) demonstrating a partially fused sagittal suture. Classic parietal and occipital narrowing is apparent.⁵

Unicoronal synostosis is involved in ~25% of nonsyndromic cases.⁶ It is characterized by anterior plagiocephaly, with ipsilateral flattening of the forehead on the affected side and contralateral bulging of the frontoparietal skull.⁵

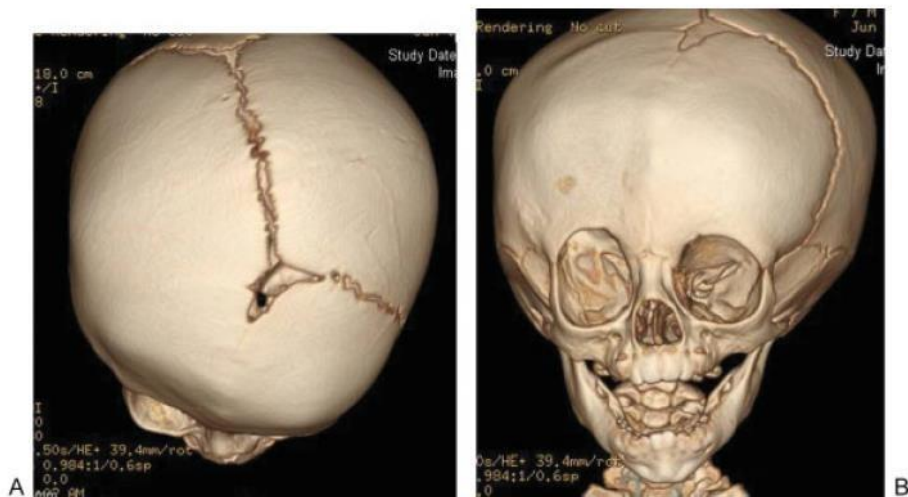


Figure 12. Three-dimensional computed tomography reconstructions of unicoronal synostosis (A) Top-down view demonstrating the unilateral forehead retrusion and anterior displacement of the zygoma on the affected side. (B) Anterior view demonstrating the periorbital deformities and maxillary rotation “facial twist,” with nasal tip deviation to the contralateral side.⁵

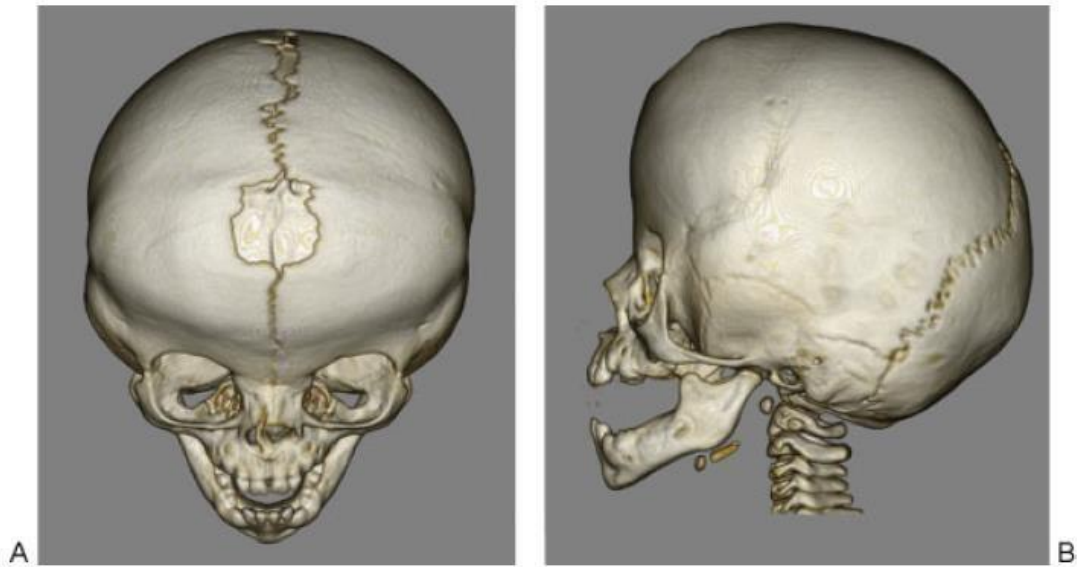


Figure 13. Three-dimensional computed tomography reconstructions of bicoronal synostosis. (A) Oblique top-down view to include the face. This demonstrates the bilateral forehead retrusion. (B) Lateral view demonstrating the typical appearance of the turribrachycephaly phenotype.⁵

Metopic synostosis also occurs in ~25% of nonsyndromic cases according to recent epidemiologic studies.⁶ Resultant trigonocephaly is characterized by a triangular-shaped forehead with bifrontal and bitemporal narrowing and parietal and occipital prominence. This also produces an appearance of hypotelorism and a low nasal dorsum with epicanthal folds.⁵

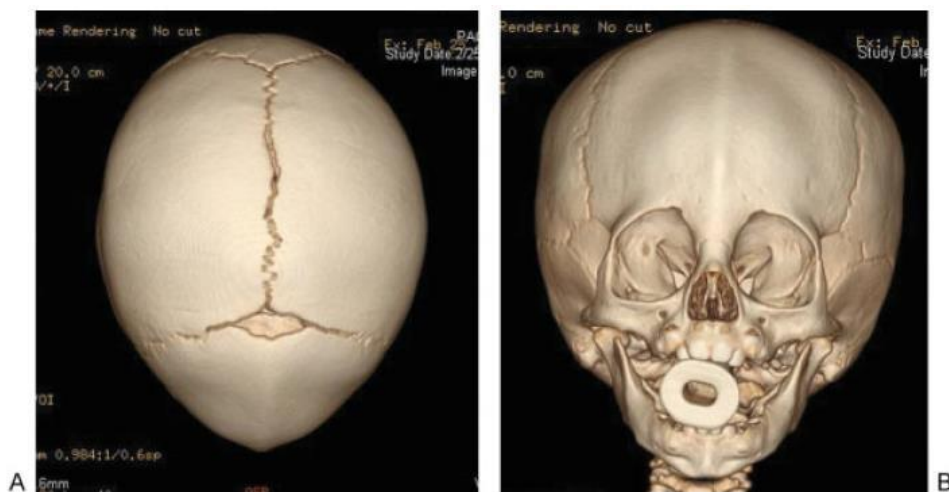


Figure 14. Three-dimensional computed tomography reconstructions of metopic synostosis. (A) Top-down view demonstrating trigonocephaly of the forehead. (B) Anterior view demonstrating the bitemporal narrowing and medialization of the superior medial orbits.⁵

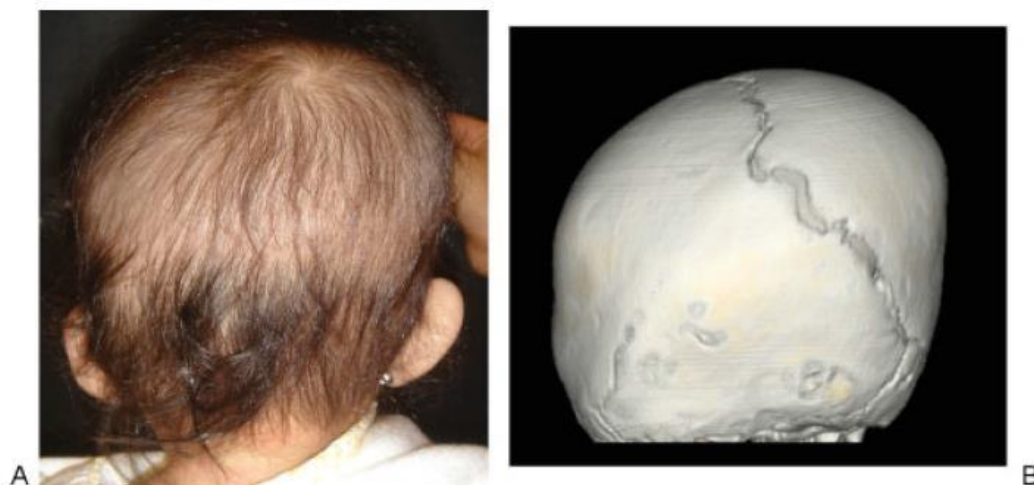

Figure 15. Unilateral lambdoid synostosis. (A) Clinical photograph of the posterior view. This shows the inferior displacement of the ear on the affected side as well as the oblique towering appearance of the skull on posterior view. (B) Three-dimensional computed tomography reconstruction (posterior view) demonstrating a partially fused left lambdoid suture. The classic mastoid bulge and tilt of the skull base is apparent.⁵



The rarest type of nonsyndromic craniosynostosis, unilateral lambdoidal synostosis, is characterized by occipital dysmorphism. The resultant phenotype has hallmark findings of an ipsilateral mastoid bulge, thickened ridging of the affected lambdoid suture, and tilt of the occipital skull base with the affected side shifted downward.⁵

2.3 Pathogenesis

The pathogenesis of CS is unclear, complex, and perhaps multifactorial, including intrinsic bone abnormalities, genetic mutations, and environmental (mechanical or biochemical) issues. CS has been associated with metabolic conditions (hypophosphatemia, rickets), and with other risk factors as follows: fetal constraint (nulliparity, plurality, macrosomia); low birth weight; hyperthyroidism; maternal smoking; pre-term delivery; exposure to teratogens; maternal consumption of valproate acid; shunted hydrocephalus, and excessive ingestion of antacids. A single genetic anomaly has not been identified as a causal factor for the condition.²

2.4 Clinical Features

Clinical findings, natural history, and management of synostotic and deformational plagiocephaly are different, and accurate diagnosis is therefore essential. In synostotic plagiocephaly, unilateral coronal synostosis results in more severe cranial distortion than unilateral lambdoid synostosis.⁶

Characteristics	Positional plagiocephaly	Lambdoid craniosynostosis
Age at onset	Several weeks postnatally	Birth
Preferred position	Common	Rare
Torticollis	Present	Absent/Present
Bony ridge along the lambdoid suture	Absent	Present
Bulging mastoid	Absent	Present
Frontal bossing	Ipsilateral	Contralateral
Displacement of the ipsilateral ear	Anterior	Posterior
Skull shape	Parallelogram	Trapezoid
		
Diagnosis	Clinical, through medical history and physical examination	Three-dimensional computed tomography
Treatment	Clinical	Surgical

3D, three-dimensional; CT, computed tomography.

Figure.16. Important characteristics to subsidize the differential diagnosis of positional plagiocephaly versus lamboid synostosis.¹¹

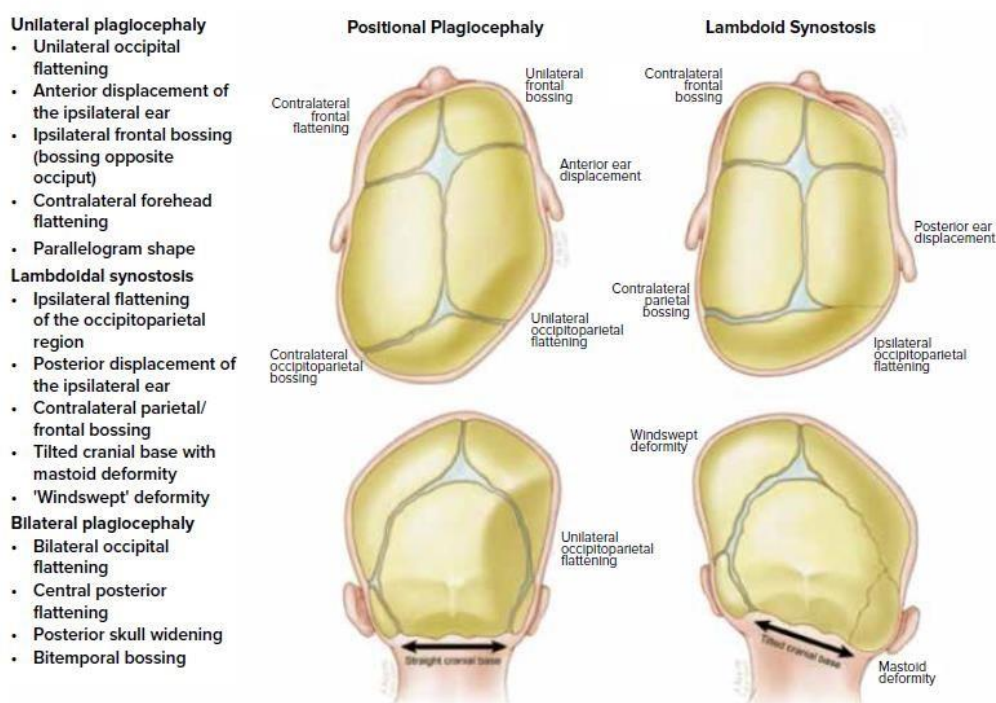


Figure 17. Positional Plagiocephaly. Adapted from International Society of Paediatric Neurosurgery (ISPN) website.¹⁷

The major functional problems associated with nonsyndromic craniosynostosis are intracranial hypertension, visual impairment, limitation of brain growth and neuropsychiatric disorders. The severity of functional disorder increases with the number of fused sutures. Headache is the classic symptom associated with increased intracranial pressure of any cause; however, children with craniosynostosis and increased intracranial pressure seem to experience headache inconsistently. Headache is most common in patients with multiple sutural synostosis and less frequent in patients with single sutural synostosis.⁶

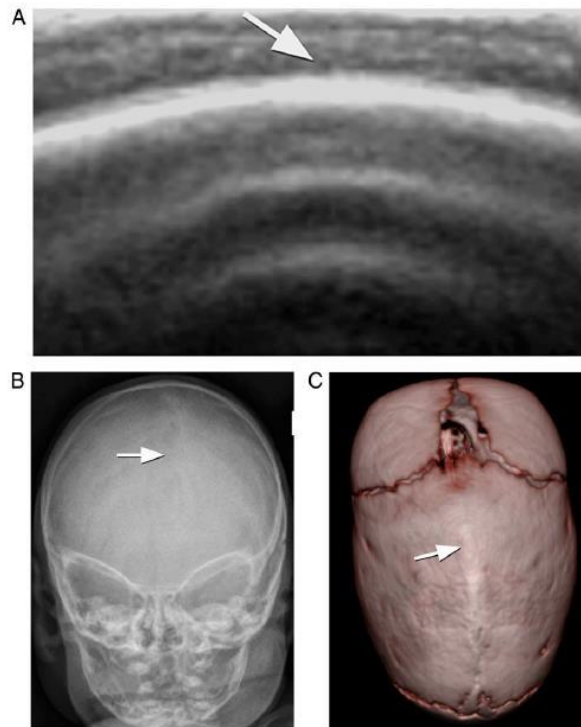


Figure 18. A, A 2-month-old boy with suspected sagittal synostosis. CUS showed obliteration of the normal hypoechogenic gap between the parietal bones, representing an abnormally closed sagittal suture (arrow). B, Frontal cranial radiograph in the same patient confirms a closed sagittal suture with some sclerosis along the suture (arrow). C, Three-dimensional reconstruction of cranial CT confirmed abnormal closure of the sagittal suture (arrow).⁸

Computed tomography (CT) is the standard method for investigating potential craniosynostosis, and it has been proposed that 3D CT imaging is essential for the diagnosis of craniosynostosis. CT scans permit excellent highdefinition images of the underlying bony architecture, and this provides invaluable guidance as a diagnostic tool for recognizing the type of anomalies and in preoperative planning of surgical correction.⁶

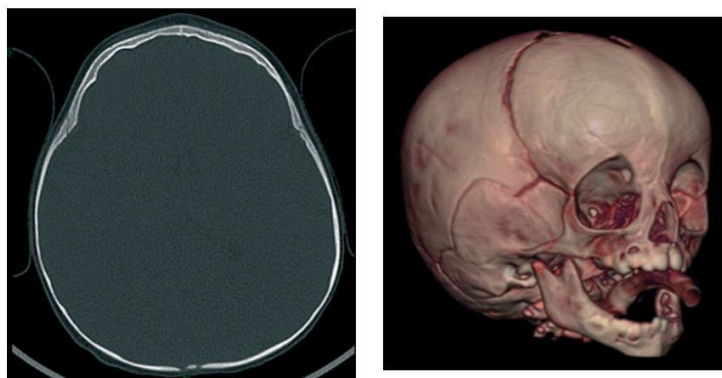


Figure 19. Computed tomography-scan of a 5-month-old child with Trigonocephaly.⁶

2.5 Treatment

If left untreated, NSCS can result in aggravated craniofacial deformities, which may lead to psychosocial issues as the child interacts with peers during development, due to visible facial differences or language/visual/behavior impairments. Affected children may have an increased risk for psychosocial and cognitive difficulties, and consequently, a diminished health-related quality of life.²

Sagittal synostosis	The main objective is anteroposterior shortening to a near-total cranial vault reconstruction. The procedure involves either strip craniectomy or cranial vault remodeling with excision of the frontal, parietal, and occipital bones, which are trimmed and reshaped.
Coronal (unicoronal or bicoronal) synostosis	The objectives are to increase the anteroposterior dimensions of the calvaria, and frontoorbital advancement (forehead and superior and lateral periorbital skeleton).
Metopic synostosis	The main goal is to increase the volume of the anterior cranial fossa. It also requires frontoorbital reconstruction.
Lamboidal (unilateral or bilateral) synostosis	The principal surgical purpose is posterior vault reconstruction through occipital and parietal craniotomies or partial craniectomy for rearrangement.

Figure 20. Surgical interventions for the different types of craniosynostosis.²

There are many techniques and modifications that have been described and/or presented. The techniques advocated are dependent on surgeon preference and experience alone, without comparative trials or agreed-upon aesthetic outcomes.⁵

a) Sagittal

Surgical approaches for correction of scaphocephaly in sagittal synostosis range from synostectomy (either endoscopic or open), a Pi procedure that involves more extensive strip craniectomy for anteroposterior shortening, to near-total cranial vault reconstruction for children.

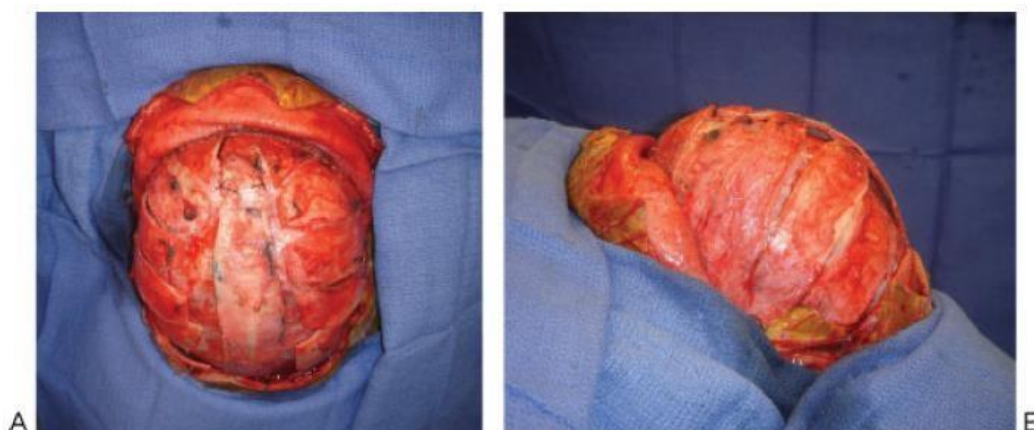


Figure 21. Intraoperative photographs of the described modified Pi procedure. (A) Posterior and vertex view with the patient in prone position. The occiput is flattened with bilateral medially based occipital wedge osteotomies. The occipital contour can be held into place with resorbable plates and screws as shown or allowed to float without fixation. (B) Lateral view with the patient in prone position. This shows the lateral barrel stave osteotomies down to the level of the squamosal sutures. The coronal suture is centered on the anteriormost barrel stave. The lambdoid suture is centered on the posteriormost barrel stave.⁵

b) Coronal

The correction of unicoronal and bicoronal synostosis requires a frontal reconstruction that addresses the superior and lateral periorbital skeleton as well as the forehead, classically described as frontoorbital advancement.⁵

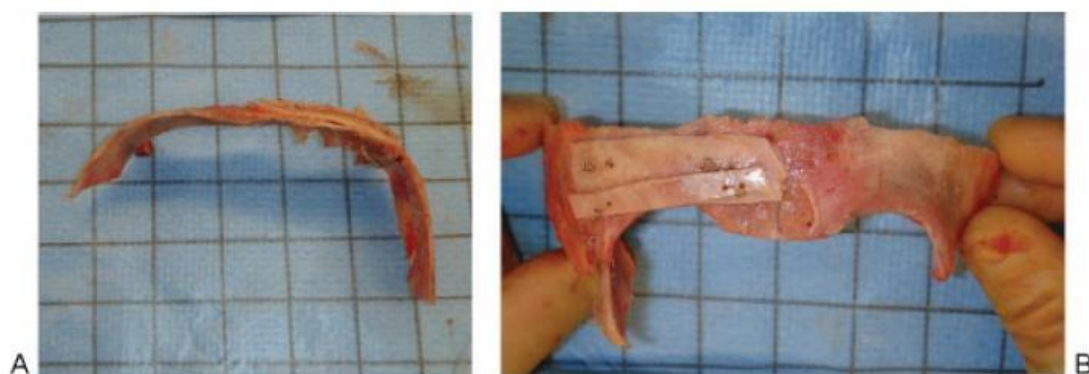


Figure 22. Reshaped frontal bandeau (ex situ) in reconstruction of unicoronal synostosis. (A) Top-down view. This shows the asymmetric design of the orbital bandeau to include a longer temporal segment on the affected side. (B) Anterior view. This shows the asymmetric design of the lateral orbital cuts. The osteotomy on the affected side is performed to include the entire lateral orbital rim down to the body of the zygoma, similar to a C-shaped osteotomy of the zygoma. Onlay bone grafts can be considered for additional brow projection on the affected side. However, the long-term viability and resorption of these grafts are unknown.⁵

This area is recontoured to decrease the width of the bandeau in this location, as it is widened by the advancement at the glabella. The lateral temporal wing is contoured by a closing wedge osteotomy and plate and screw stabilization.⁵

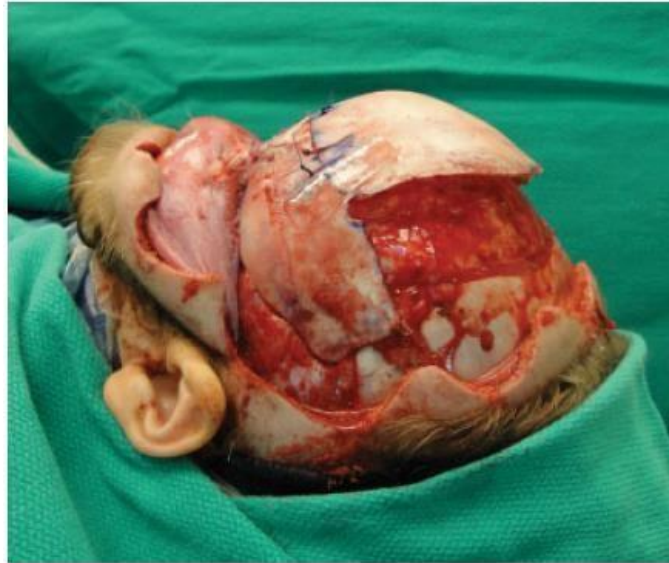

Figure 23. Lateral view of the frontal bandeau and frontal bone placed back in situ. The frontal bandeau is advanced and twisted, which rotates the temporal wing of the bandeaus superiorly. This maneuver produces enhanced brow prominence. The bifrontal bone is contoured to the reconstructed bandeau configuration and replaced as a single unit.⁵

These techniques are modified for treatment of bicoronal synostosis. The lateral orbital rims and C-shaped osteotomies are performed on both sides, as both lateral orbital rims need to be brought forward. The lateral temporal wings of the bandeau are extended bilaterally.⁵

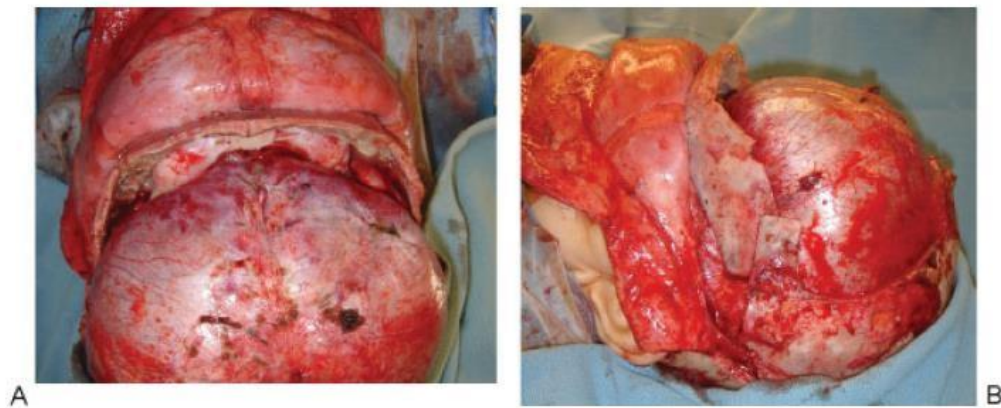


Figure 24. Reconstructed in situ appearance of the frontal bandeau. (A) Top-down view demonstrating the significant improvement in intracranial volume after appropriate advancement and twist of the frontal bandeau with fixation to the nasofrontal region and zygoma bilaterally. (B) Lateral view of the frontal bandeau showing the desired position of the temporal wings of the bandeau after the advancement and twist maneuver.⁵

c) Metopic

Metopic craniosynostosis must be distinguished from a benign, normally fused metopic ridge. The metopic suture fuses after birth in most patients before 1 year of age, with progression of closure from nasion to anterior fontanelle.⁵

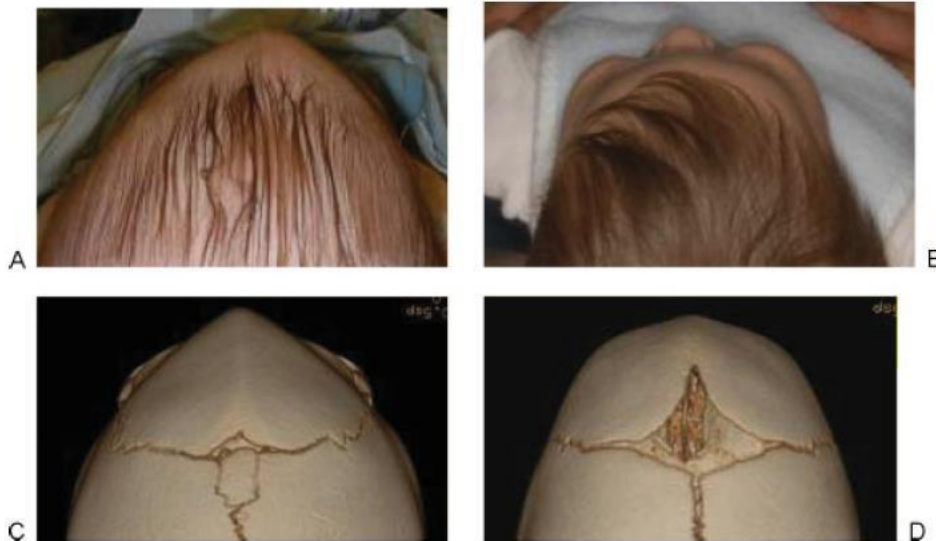


Figure 25. Forehead contour of metopic synostosis versus benign metopic ridge. (A) Typical view of forehead contour in a patient with metopic synostosis. The classic features of trigonocephaly are apparent. (B) Typical view of the forehead contour in a patient with benign metopic ridge. The forehead is normally round without trigonocephaly and normal bitemporal width. (C) Three-dimensional computed tomography reconstruction of the forehead contour in metopic synostosis. (D) Three-dimensional computed tomography reconstruction of the forehead contour in benign metopic ridge.⁵

Surgical correction for metopic craniosynostosis also requires a frontal reconstruction that addresses the superior and lateral periorbital skeleton as well as the forehead. This procedure is preferably done between 8 and 12 months of age. Most surgeons choose an open approach that allows for complete frontoorbital advancement.⁵

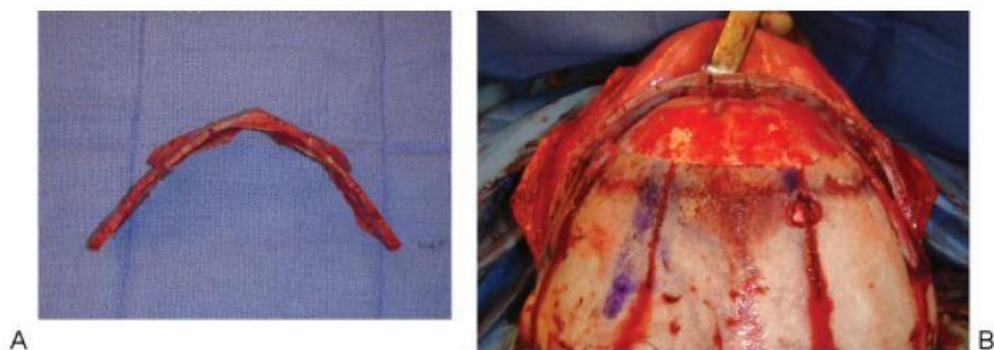


Figure 26. Frontal bandeau inmetopic craniosynostosis. (A) Top-down view of the frontal bandeau ex situ prior to reshaping. (B) Top-down view of the frontal bandeau back in situ after reshaping.⁵

d) Lambdoidal

Correction of either unilateral or bilateral lambdoidal synostosis requires bilateral occipital and parietal reconstruction. Posterior vault reconstruction is performed between 3 and 6months of age in prone position.⁵

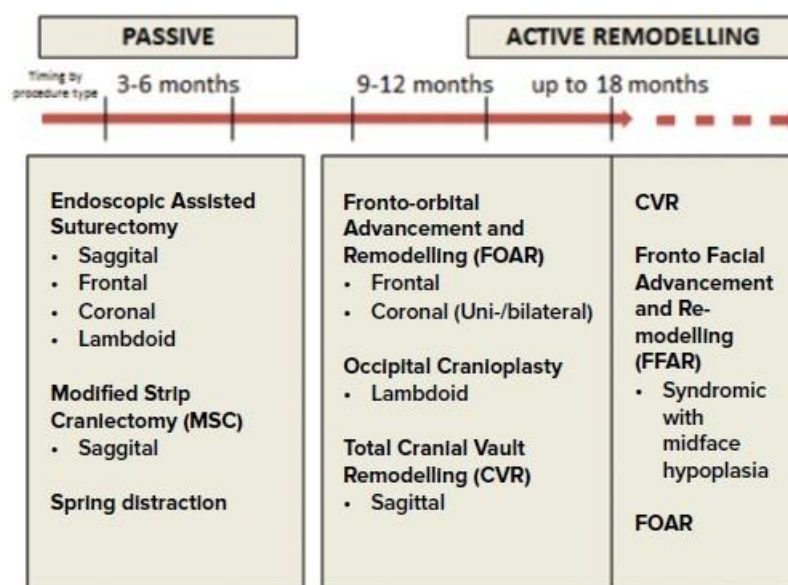


Figure 27. Overview on operative techniques for simple craniosynostosis. Early surgery allows for brain growth to passively reshape skull.¹⁷

2.6 Complication and Outcomes

Acute complications following open surgical repair of craniosynostosis include bleeding, infection, CSF leak, meningitis, stroke, and even death. Reported postoperative complications include infection, failure of reossification, contour irregularity, and need for reoperation.¹⁴

3. Syndromic Craniosynostosis

3.1 Incidence

The overall incidence of craniosynostosis is estimated at between 1 in 2,100 and 1 in 2,500 live births, but this varies greatly depending on the suture(s) involved. The most frequently diagnosed craniosynostosis-associated syndromes include Muenke (1 in 10,000–1 in

30,000), Crouzon (1 in 25,000), Pfeiffer (1 in 100,000), Apert (1 in 100,000), and Saethre-Chotzen (1 in 25,000–50,000).¹

3.2 Pathogenesis

The genes most frequently involved in CS include those encoding for the different fibroblast growth-factor receptors; these mutations lead to defects in signaling and tissue interactions, resulting in abnormal suture maturation and cranial malformation, particularly in the syndromic type.²

Syndrome	Gene	Inheritance	Sutures Affected	Craniofacial Features	Systemic Features	Hydrocephalus Reported?
Apert	<i>FGFR2</i>	Autosomal dominant	Coronal	Midface hypoplasia, hypertelorism	Syndactyly of hands/feet, cervical vertebral fusion, hearing loss	Yes
Crouzon	<i>FGFR2</i> , <i>FGFR3</i>	Autosomal dominant	Coronal, sagittal, and/or lambdoid	Midface hypoplasia, exophthalmos, hypertelorism	Cervical vertebral fusion, hearing loss	Yes
Pfeiffer	<i>FGFR1</i> , <i>FGFR2</i>	Autosomal dominant	Coronal and/or sagittal, possible cloverleaf	Midface hypoplasia, hypertelorism	Broad thumbs/great toes, brachydactyly, syndactyly, cervical vertebral fusion, hearing loss	Yes
Muenke	<i>FGFR3</i>	Autosomal dominant	Coronal (unilateral or bilateral)	Midface hypoplasia, Hypertelorism, macrocephaly	Hearing loss	Yes
Saethre-Chotzen	<i>TWIST1</i> , <i>FGFR2</i>	Autosomal dominant	Coronal, lambdoid, and/or metopic	Parietal foramina	Syndactyly, heart defects	Yes
Antley-Bixler	<i>FGFR2</i>	Autosomal recessive	Coronal and/or lambdoid	Midface hypoplasia, choanal atresia	Joint contractures, radiohumeral synostosis	Yes

Figure 28. Summary of Craniosynostosis Syndromes¹⁶

3.3 Classification

a) Apert Syndrome

The clinical features of Apert syndrome include misshapen skull caused by coronal suture synostosis, wide-set eyes, mid-face hypoplasia, choanal stenosis, and shallow orbits.⁶

b) Crouzon Syndrome

In Crouzon syndrome, clinical findings include brachycephalic craniosynostosis, significant hypertelorism, proptosis, maxillary hypoplasia, beaked nose and, possibly, cleft palate. Intracranial anomalies include hydrocephalus, Chiari 1 malformation and hind-brain herniation (70%). Pathology of the ear and cervical spine is common.⁶

c) Pfeiffer Syndrome

Pfeiffer syndrome also occurs in 1 in 100,000 live births, most commonly due to *FGFR2* mutations, but *FGFR1* mutations have been found in 5% of cases, causing a

less severe presentation.⁶¹ The coronal, lambdoid and sagittal sutures are all affected, but heterogeneity of the syndrome has led to a classification into three clinical types.¹²

d) Muenke Syndrome

Muenke syndrome was genetically described in 1997 and is now the most common syndromic presentation with a prevalence of 1 in 10,000– 30,000 live. This syndrome results from mutation c.749C>G in the FGFR3 gene, resulting in p.Pro250Arg.¹

e) Saethre-Chotzen Syndrome

Saethre-Chotzen is found in 1 in 25,000 to 50,000 newborns and caused by mutations in TWIST1. The phenotype is heterogenous and synostosis can be bicoronal, unicoronal, sagittal, metopic or multisutural⁶³ leading to a great variety of head shapes.¹⁷

Syndrome	Gene	Inheritance	Craniofacial Phenotype	Associated Anomalies	Cognition
Crouzon	<i>FGFR2</i>	Autosomal dominant or sporadic	Brachycephaly; shallow orbits with ocular proptosis; constricted, high-arched palate; midface hypoplasia; anterior open bite	None	Normal
Apert	<i>FGFR2</i>	Autosomal dominant possible; mostly sporadic	Turribrachycephaly; large anterior fontanelle with bitemporal widening and occipital flattening; shallow orbits with ocular proptosis and horizontal grooves above supraorbital ridges, mild hypertelorism, and down-slanting palpebral fissures; high arched or cleft palate; severe midface hypoplasia; anterior open bite; "parrot beak" nasal deformity	Symmetric syndactyly of both hands and feet (often involving fusion of the second, third, and fourth fingers and/or toes); acne vulgaris during adolescence	Significantly increased incidence of intellectual disability
Pfeiffer	<i>FGFR2</i>	Autosomal dominant or sporadic	Type I (classic Pfeiffer syndrome): turribrachycephaly; midface hypoplasia; exorbitism, hypertelorism, strabismus, down-slanting palpebral fissures; beaked nasal deformity; anterior open bite	Broad thumbs; broad great toes; variable feature, partial soft-tissue syndactyly of the hands; severe CNS involvement such as hydrocephalus (type II)	Normal or nearly normal (type I)
	<i>FGFR1</i>		Type II: associated with kleeblattschädel (cloverleaf skull); severe ocular proptosis Type III: severe ocular proptosis; shallow orbits; marked shortness of the anterior cranial base; no kleeblattschädel (cloverleaf skull)		
Muenke	<i>FGFR3</i>	Autosomal dominant or sporadic	Craniosynostosis of coronal sutures; uncommon to have midface hypoplasia	Hearing loss; thimble-like middle phalanges	Increased incidence of intellectual disability
Saethre-Chotzen	<i>TWIST1</i>	Autosomal dominant or sporadic	Heterogeneous patterns of craniosynostosis; low frontal hairline; eyelid ptosis; facial asymmetry; deviated nasal septum; ear deformities with prominent crus helcis extending through the conchal bowl; uncommon to have midface hypoplasia	Hearing loss; brachydactyly, syndactyly, and/or clinodactyly	Usually normal

Figure 29. Clinical Characteristics of the Five Major Types of Syndromic Craniosynostosis Syndromes.¹³

3.4 Diagnostic Criteria

The patient is scored across all parameters with a composite Great Ormond Street Craniofacial Outcome Score, demonstrating a score utilised as an indication of intervention or a measure of change related to surgery or treatment.¹

Syndrome	Raised ICP	Airway compromise	Exorbitism	Midface hypoplasia	Hyper-telorism	Operative intervention	Hand involvement	Other features
Apert	++	++	++ Class III	+++	++	PVE then bipartition or LFII/III	+++	Cleft, OSA, strabismus, developmental delay
Crouzon	++	++	++ Class III	++/+	-	PVE +/- monobloc	-	Cervical vertebral fusion
Pfeiffer	+++	+++	+++ Class III	+++	+/-	PVE +/- early monobloc	Broad deviated thumbs and toes	Multi-level airway anomalies, Chiari, spinal anomalies
Muenke	+	-	-	-	-	PVE +/- FOR	-	Hearing loss, seizures
Saethre-Chotzen	+	-	+/- Often class III	+/-	-	PVE +/- FOR, FOR, rarely midface	+/-mild	Ptosis, strabismus, ear anomaly
CFND	-	-	-	-	+++	Hypertelorism correction +/- FOR +/- PVE	-	Wiry hair, nail anomalies, strabismus, cleft, CNS anomalies
TCF12	+/-	-	-	-	-	PVE +/- FOR, FOR	-	Severe turribrachycephaly
ERF	++	-	+ Class III	+	+	Late vault expansion	-	Behavioural issues, hearing loss, Chiari, language delays

CFND, craniofrontonasal dysplasia; FOR, fronto-orbital remodelling; ICP, intracranial pressure; LF, Le Fort fracture; OSA, obstructive sleep apnea; PVE, posterior vault expansion. +, mild; ++, moderate; +++, severe; -, not present; +/-, sporadically.

Figure 30. Clinical features associated with syndromic craniosynostosis

The frequency of CFA and CRANF assessment for syndromic patients was:¹

- From 0–2 years old: CFA 6 monthly
- From 2–6 years old: CFA yearly and consultant review yearly alternating 6 monthly
- From 6–10 years old: CRANF yearly
- At 10 years: CFA and CRANF together
- At 12 years: CRANF review
- At 14 years: CRANF transition review (transition clinic to start process)
- At 16 years: CRANF transition review and establishment in adult services

Patients with suspected syndromic craniosynostosis, familial craniosynostosis, and clinically non-syndromic coronal or multisuture craniosynostosis have lymphocyte DNA collected for genetic testing. Screening of the FGFR1 , FGFR2 , FGFR3 , TWIST1 , ERF , TCF12 , IL11RA , and EFNB1 genes is carried out using next-generation sequencing (Agilent SureSelect and Illumina NextSeq).⁶

3.5 Management

So many techniques are described in craniofacial surgery to achieve the same aim – that of normal growth of the brain and skull enabling optimal development. Surgical techniques

continue with exponential innovation in a desire to make procedures less invasive with a reduced complication profile.¹

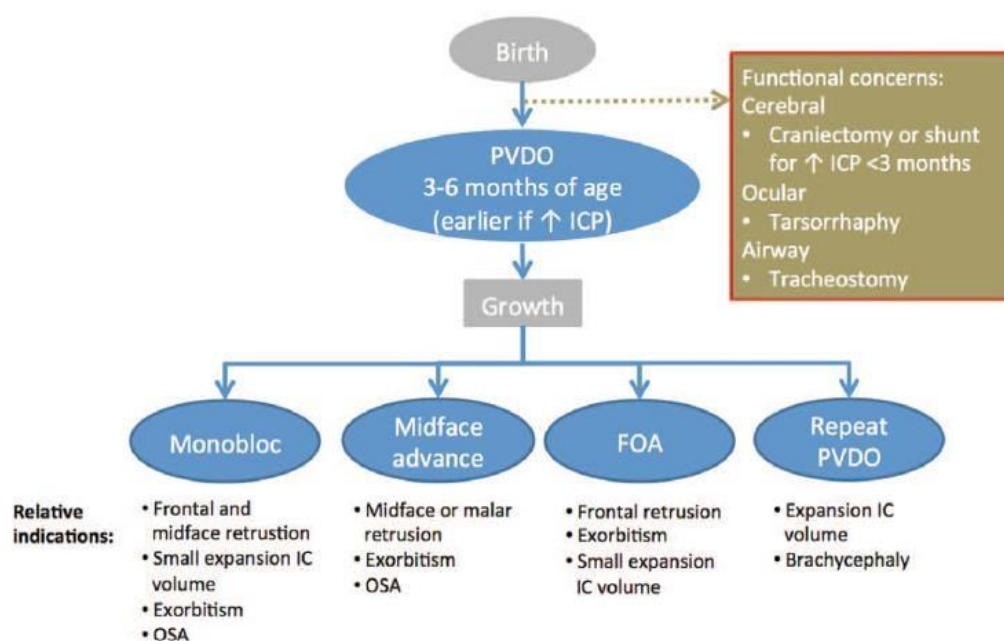


Figure 31. The Children’s Hospital of Philadelphia algorithm for management of children with syndromic craniosynostosis.¹²

Surgery	Age	Indication	Position	Anaesthetic considerations	Length of procedure
Extended strip craniectomy	4-6 months	Usually sagittal synostosis	Supine, head-up tilt	Young infant Oral or nasal TT Arterial line May require redo surgery	1-3 h
Spring-assisted cranioplasty	4-6 months	Sagittal synostosis, Scaphalocephaly or posterior plagiocephaly	Supine, head-up tilt	May not need invasive monitoring in some procedures	45 min-1.5 h
Total vault reconstruction	>10-12 months	Usually sagittal synostosis	Modified prone with head extension	Oral or nasal TT Arterial line Cell salvage	4-6 h
Minimally invasive endoscopic surgery	<3 months (3-6 months acceptable)	Usually sagittal, also metopic, coronal	Supine or modified prone position	Blood transfusion uncommon May not need invasive monitoring May be discharged day 1 postop	1-2 h
Fronto-orbital remodelling	Between 12 and 18 months	Metopic, coronal synostosis	Supine, head-up tilt	South facing RAE TT Lacrilube to eyes Arterial line	3-4 h
Posterior calvarial vault expansion	6 months or younger	Lamboidal synostosis	Modified prone with head extension	Arterial line Oral or nasal TT	2-3 h

Figure 32. Surgery for craniosynostosis

a) Surgery Under 1 Year of Age

The goals of surgical treatment in the first year of life are to increase the intracranial volume, with the aim of reducing the risk of developing elevated ICP and to improve head shape.³

- **Posterior Vault Distraction**

The advantages of distraction osteogenesis have been highlighted by its application in the cranial vault, midface, and mandible including the maintenance of bone vascularity, production of vascularized bone, limiting production of dead space, and gradual expansion of the soft tissue envelope that allows for greater advances to be achieved and maintained in the jaws.³

- **Spring-Assisted Cranioplasty**

Spring-assisted cranioplasty (SAC) uses continuous force generated by a spring across either an osteotomy or a patent suture to achieve a change in head shape and expand the intracranial volume.³

- **Frontoorbital Advancement**

The surgical goals of a frontoorbital advancement (FOA) are to expand intracranial volume, reshape the cranial vault, and advance the retruded supraorbital bar to improve globe protection and aesthetic appearance.³

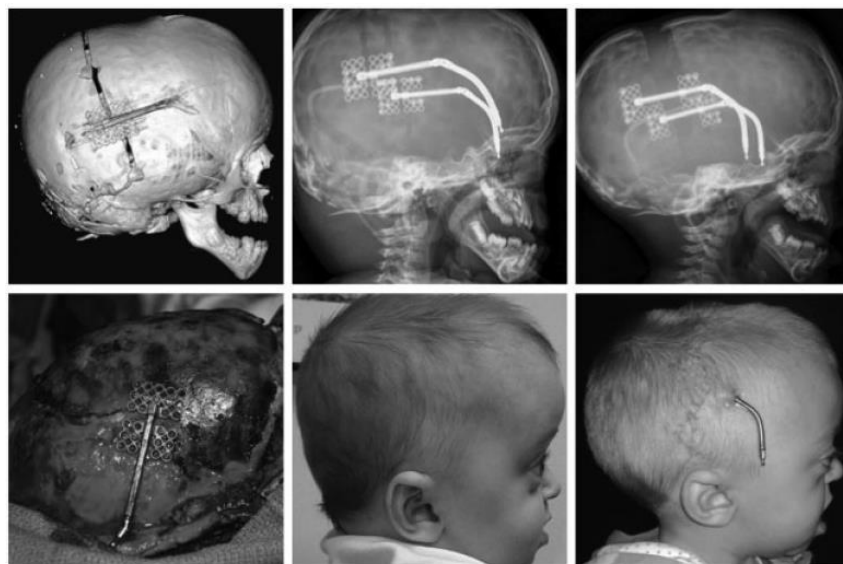


Figure 33. This figure demonstrates distraction osteogenesis of the posterior cranial vault. The left images are three-dimensional computed tomography and intraoperative views of the osteotomies and distraction device placement. The middle images are radiographic and clinical views prior to distraction; the right images are the same views at the end of the activation phase of distraction osteogenesis.³

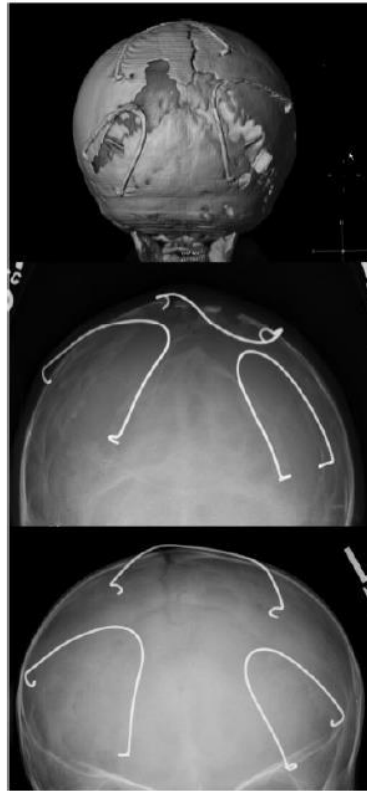


Figure 34. This girl with Apert syndrome underwent spring cranioplasty of her posterior scalp. The top image demonstrates the position of the springs on the skull, the middle radiograph shows the spring position immediately following placement, and the lower radiograph shows the spring position 6 months later.

Anterior cranial vault remodeling technique is dependent on the preoperative head shape. For severe turricephaly, a total cranial vault reshaping can be performed that allows for a significant reduction in the vertical height of the skull. Patients with less severe turricephaly, as often seen after PVD, typically require only the anterior two-thirds of the vault remodeled.³

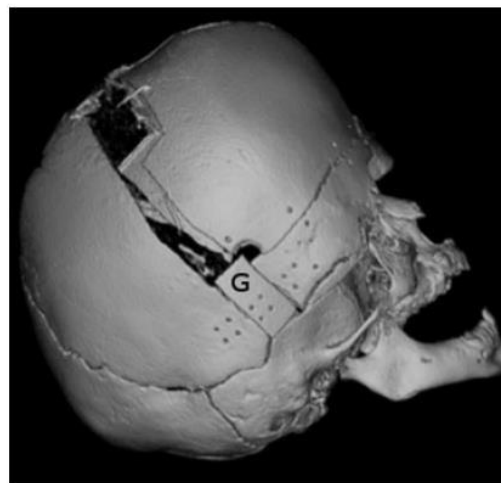


Figure 35. This three-dimensional computed tomography reconstruction demonstrates the frontoorbital bandeau, cut at the posterior level of the osteotomy, bolstered forward with bone graft. The graft is marked “G” and the posterior end of the bandeau lies immediately anterior to the graft.³

b) Surgery in Midchildhood

- **Midface advancement**

The timing of midface correction remains controversial among craniofacial surgeons. Some craniofacial centers advocate early surgical correction between the ages of 4 and 7 years, whereas others prefer to wait until full skeletal maturity is reached unless airway obstruction or severe exorbitism warrant early intervention.³

The final occlusion is addressed with the definitive orthognathic procedure once the patient reaches skeletal maturity, and occlusion should play little-to-no role in the planning of these procedures.³

c) Surgery in Adolescence

- **Orthognathic Surgery**

The abnormal patterns of facial growth in children with craniosynostosis syndromes often result in significant dentofacial deformities. Class III malocclusion, secondary to midface hypoplasia, is the most commonly seen deformity and often develops despite appropriate midface surgical treatment.³

- **Final Facial Contouring**

At the completion of facial growth and all major osteotomies, contour irregularities of the facial skeleton may still remain. Final contouring procedures are often performed at this time.³

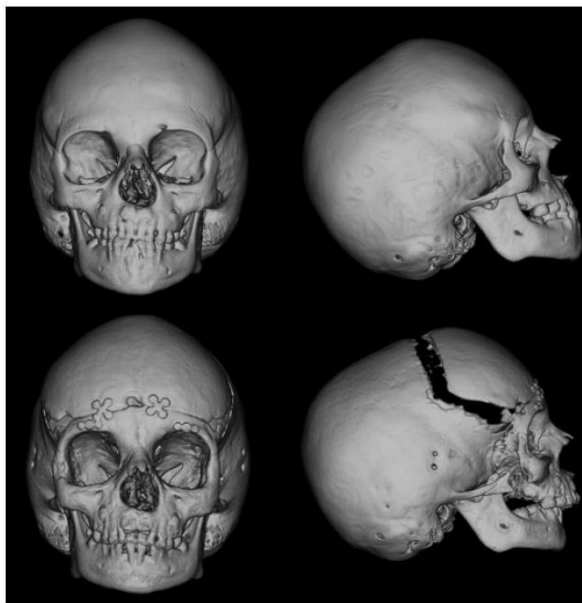

Figure 36. These three-dimensional computed tomography reconstructions demonstrate a monobloc distraction. The top images are anteroposterior and lateral views preoperatively and the lower images are the same views following post-consolidation.³

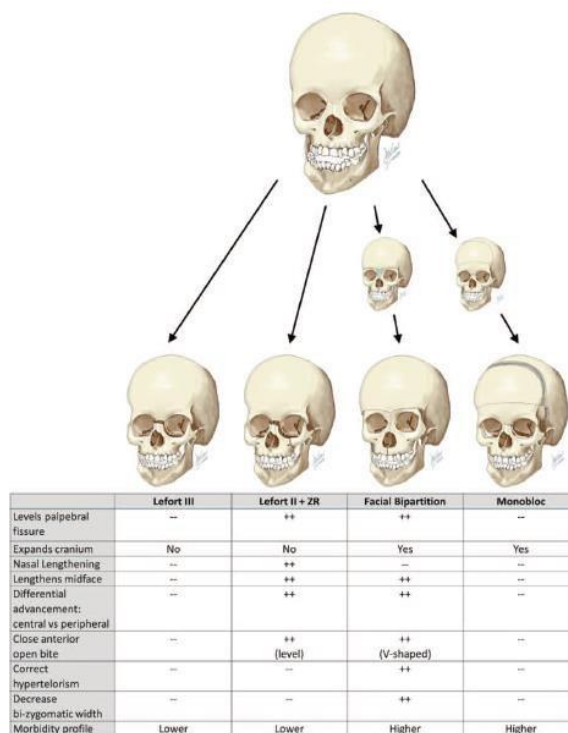


Figure 37. Options for midface osteotomy in children with syndromic craniosynostosis, which include Le Fort III, Le Fort II with zygomatic repositioning, monobloc, and monobloc with facial bipartition. The table below the line drawings provides a comparative risk-to-benefit assessment of the various options.¹³

3.6 Complication

Regardless of the type or etiology, among craniofacial anomalies, this group represents a significant array of pathologies that may impair different functions of the central nervous system (CNS) during development of the children. These impairments imply the need for multidisciplinary care, with a varied staff of specialists, including plastic surgeons, neurosurgeons, geneticists, dentists, neurologists, speech language pathologists, ear, nose and throat doctors, orthopedists, social workers, and others.¹⁵

Symptoms

- Bronchoconstriction/wheezing
- Hypotension/circulatory collapse
- Hypoxaemia (V/Q mismatch)
- Dysrhythmias
- Myocardial ischaemia

Signs

- Abrupt decrease/loss end-tidal CO₂
- Turbulent flow detected on transoesophageal echo or Doppler ultrasound

Management

- Notify surgeon, call for help
 - 100% oxygen
 - Discontinue nitrous oxide/volatile
 - Flood surgical wound with saline
 - Position head below the heart
 - Perform valsalva with manual ventilation
 - Chest compressions (even if not in cardiac arrest, these may help break up bubbles)
 - Treat cardiovascular compromise with usual inotropes, e.g. epinephrine
 - Standard PALS protocol if in cardiac arrest
 - Call for emergent transoesophageal echocardiography to confirm diagnosis
-

Figure 38. Intraoperative Venous air embolism.¹⁹

Careful attention should be paid to postoperative electrolyte disturbances, particularly hyponatraemia. This may be related partly to the use of crystalloid infusions intraoperatively and also to anti-diuretic hormone release (SIADH) as a result of the surgical insult.¹⁹

Conclusion

Craniosynostosis is a congenital cranial malformation in which one or more cranial sutures have fused already in utero. The cranial sutures separate the skull bone plates and enable rapid growth of the skull in the first 2 years of life, in which growth is largely dictated by growth of the brain. Each suture is composed by a dense fibrous connection that separates the individual cranial bones. In syndromic craniosynostosis, other birth defects are present next to the craniosynostosis. In syndromic craniosynostosis, usually more than one cranial sutures have prematurely fused, typically involving both coronal sutures. Normal cranial development,

clinical manifestations, and pathogenesis of NCSC. During normal human body and head development, cranial growth achieves approximately 80% of the adult size at birth and its definitive size between 2.5 and 3 years of age. In the fetal or newborn skull, the flat bones are separated by four fontanelles and six major cranial sutures that participate in this process.

REFERENCES

- [1] O'Hara J, Ruggiero F, Wilson L, James G, Glass G, Jeelani O. et al. Syndromic Craniosynostosis: Complexities of Clinical Care. *Mol Syndromol*. 2019; 10: 83-97.
- [2] Garrocho-Rangel A, Manríquez-Olmos L, Flores-Velázquez J, Rosales-Berber MA, Martínez-Rider R, Pozos-Guillén A. Non-syndromic craniosynostosis in children: Scoping review. *Med Oral Patol Oral Cir Bucal*. 2018 Jul 1;23 (4):e421-8.
- [3] Derderian C, Seaward J. Syndromic Craniosynostosis. *Semin Plast Surg* 2012;26:64–75
- [4] Mathijssen IMJ. Guideline for Care of Patients With the Diagnoses of Craniosynostosis: Working Group on Craniosynostosis. *J Craniofac Surg* 2015;26: 1735–1807
- [5] Garza RM; Khosla RK. Nonsyndromic Craniosynostosis. *Semin Plast Surg* 2012;26:53–63.
- [6] Ursiti F, Fadda T, Papetti L, Pagnoni M, Nicita F, Lannetti G. et al. Evaluation and management of non syndromic craniosynostosis. *Acta Paediatrica*. 2011; 100: 1185-1194.
- [7] Coyotl DMC, Huerta XOR, Vazquez JJS, Sanchez MID, Peralta JSR, Munive JMT. et al. Guide to clinical practice for the diagnosis, treatment and rehabilitation of non-syndromic craniosynostosis on 3 levels of care. *Cirugía y Cirujanos*. 2017;85(5):401---410.
- [8] Rozovsky K, Udjus K, Wilson N. et al. Cranial Ultrasound as a First-Line Imaging Examination for Craniosynostosis. *Pediatrics*. 2016;137(2):e20152230
- [9] Goos JAC, Mathijssen IMJ. Genetic Causes of Craniosynostosis: An Update. *Mol Syndromol* 2019;10:6–23
- [10] Fabian A. Surgical Management of Complex Craniosynostosis, Case Reports Interdisciplinary Experience. *Frontiers in Medical Case Reports*. 2020; 1(1): 1-17.
- [11] Ghizoni E, Denadai R, Raposo-Amaral CA, Joaquim AF, Tedeschi H, Raposo-Amaral CE. Diagnosis of infant synostotic and nonsynostotic cranial deformities: a review for pediatricians. *Rev Paul Pediatr*. 2016;34(4):495---502
- [12] Swanson JW, Samra F, Bauder A, Mitchell BT, Taylor JA, Bartlett SP. An algorithm for managing syndromic craniosynostosis using posterior vault distraction osteogenesis. *Plast Reconstr Surg*. 2016;137:829e–841e. Available from: <https://pubmed.ncbi.nlm.nih.gov/27119945/> [Accessed on 13 October 2020]

- [13] Taylor JA. Bartlett SP. What's New in Syndromic Craniosynostosis Surgery? *Plast Reconstr. Surg.* 2017. 140: 82e
- [14] Kuta V. Curry L. McNeely D. et al. Understanding families' experiences following a diagnosis of non-syndromic craniosynostosis: a qualitative study. *BMJ Open* 2020;10:e033403. doi:10.1136/bmjopen-2019-033403
- [15] Maximino LP. Ducati LG. Abramides DVM. Correa CC. Garcia PF. Fernandes AY. Syndromic craniosynostosis: neuropsycholinguistic abilities and imaging analysis of the central nervous system. *Arq Neuropsiquiatr* 2017;75(12):862-868
- [16] Governale LS. Craniosynostosis. *Pediatric Neurology.* 2015; 53: 394-401.
- [17] Jung J, Lam J, deSouza R-M, Anderson I, Chumas P. Craniosynostosis. *ACNR* 2018;18(2):5-11.
- [18] Shim KW. Park EK. Kim JS. Kim YO. Kim DS. Neurodevelopmental Problems in Non-Syndromic Craniosynostosis. *J Korean Neurosurg Soc.* 2016; 59(3): 242-246.
- [19] Pearson A. Matava CT. Anaesthetic management for craniosynostosis repair in children. *BJA Education.* 2016. 16(12): 410-416.
- [20] Johnson D. Wilkie AOM. Craniosynostosis. *European Journal of Human Genetics.* 2011; 19: 369-376.