

Frontoorbital Advancement (FOA) Using Surgical Suture, Our Experience : Single Institution

Samsul Ashari¹, K M A Halim Habibi²

¹Head of Division of Paediatric Neurosurgery, Department of Neurosurgery, Faculty of Medicine, University of Indonesia, Dr. Cipto Mangunkusumo General Hospital, Jakarta

²Resident of Neurosurgery, Department of Neurosurgery, Faculty of Medicine, University of Indonesia, Dr. Cipto Mangunkusumo General Hospital, Jakarta

Abstract

Introduction : Fronto-orbital advancement (FOA) was mainstay treatment of coronal and metopic craniosynostosis. There are several techniques and materials such as absorbable plate, surgical suture fixation, and osteogenesis distraction. Each techniques and materials has advantages to clinical outcome. This study describe our experience in FOA using surgical suture in our Institution.

Method : A retrospective chart review was conducted on cases involving patients with nonsyndromic metopic and bicoronal craniosynostoses admitted to Ciptomangunkusumo Hospital in Jakarta for frontoorbital advancement from 2018 through 2020.

Results : A total of four patients underwent surgery between January 2018 to December 2020. The study group include two males and two females. All of them had complex craniosynostosis. The mean age was 27,25 months. The mean blood loss was 197,5 ml. The mean operative time was 328 minutes. The mean length of hospital stay was 5,23 days.

Conclusion : Using surgical suture shown effective and efficient in line with today's healthcare environment that requires hospitals to continue to maintain quality standards while lowering material costs to remain financially viable.

Keyword : Frontoorbital advancement, Craniosynostosis, Surgical suture

Introduction

Craniosynostosis is the premature closure of sutures in the cranial vault, and it occurs in 1/2500 births [1]. Coronal craniosynostosis is the second most common sutural fusion and occurs at a rate of 1 in 10.000 children [2]. To date, frontoorbital remodeling surgery remains the standard of care for metopic and unicoronal craniosynostosis treatment, with techniques varying between centers. Tessier's tongue-in-groove advancement of the roof of the orbits followed by an attachment of a reconstructed forehead bone still remains one of the most commonly reported techniques [3].

Despite this advance, there still remain risks of postoperative complications when using absorbable hardware [3]. However, hydrolytic foreign body reaction, loss of tensile strength, less stabilisation and more difficult handling have been reported with the implementation of this method [4]. In addition, reports have shown that the use of absorbable plates increases the operation time due to the extra need for tapping the screw hole and the risk of screw fracture, when the screws are not applied accurately in an orthograde direction [5]. Similarly, published complications associated with resorbable materials are soft-tissue swelling, osteolysis and sterile fistulas, as well as the problem of palpability of the implanted plate resulting in a significant bulge preceding the complete degradation [6].

*Corresponding author at: Department of Neurosurgery, Faculty of Medicine, University of Indonesia, Dr. Cipto Mangunkusumo General Hospital, Jakarta

The purpose of the study were to investigate and evaluate the efficacy of surgical sutures in our series of craniosynostosis patients.

Methods

A retrospective chart review was conducted on cases involving patients with nonsyndromic metopic and bicoronal craniosynostoses admitted to Ciptomangunkusumo Hospital in Jakarta for frontoorbital advancement from 2018 through 2020.

Operative technique

Coronal incision started from 1cm anterior tragus to vertex using scalpel. Galea undermined until superior orbit is identified, then bicoronal flap elevated. Periosteum incised 1 cm cranial to superior orbital rim bilateral, which it will passed by craniotom then subperiosteal dissected using raspatorium, supraorbital nerves is preserved, identification of nasofrontal suture, temporalis muscle dissected subperiosteal until zygomaticofrontal suture exposed. Two bur holes are made at point which made by intersection of horizontal line 1 cm cranial to superior orbital rim and coronal suture.

Craniotomy was made 0.5 cm anterior to coronal suture then continued horizontally cranial to superior orbital rim, bone flap detached from duramater, then duramater covered by spongostan. Osteotomies are then performed 2 cm lateral to left zygoma through frontozygoma suture, orbital roof bilateral, nasofrontal suture then 2 cm lateral to right zygoma. Frontal bone flap divided in midline using craniotom if metopic suture closed, then inferior part of bone flap cut in 1 cm. Inferior part of bone flap reconstructed in 1 x 1.5 cm, then attached to supraorbital bar, using prolene 3/0. Frontal bone flap than rotated and attached to orbital bar using prolene 3/0. Bone flap then returned, orbital part then fixated to temporal bone using prolene 3/0, frontal part then fixated to duramater using silk 4/0. The coronal flap is pulled back over the reconstruction, then sutured layer by layer.

Radiological Assessment

3D CT was used to evaluate bone fusion and longitudinal orbital projection before and after FOA. Bone fusion was fusion between bone flap including orbital bar to adjacent bone. Longitudinal orbital projection was plane connecting the apex of the orbit and the center of the globe [8].

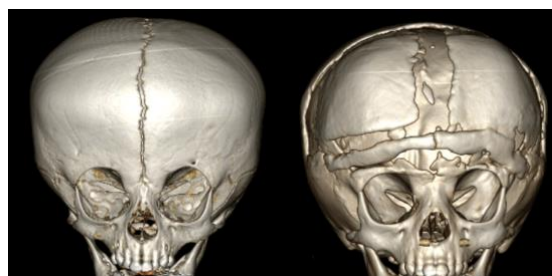


Figure 1. Preoperative and post operative 3D CT

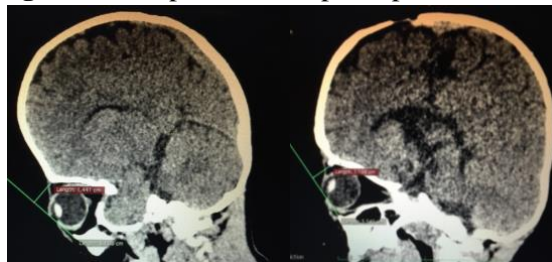

Figure 2. Left side is preoperative longitudinal orbital projection and right side is postoperative measurement. There was decreasing value after advancement.

Results

A total of four patients underwent surgery between January 2018 to December 2020. The study group include two males and two females. All of them had complex craniosynostosis. The mean age was 27,25 months. The mean blood loss was 197,5 ml. The mean operative time was 328 minutes. The mean length of hospital stay was 5,23 days.

Table 1 Comparison of Bone Fusion and Longitudinal Orbital Projection pre and post FOA

No	Bone Fusion	Longitudinal orbital projection (cm)			Length of follow up (month)
		Pre Op	Post op	Difference	
1	+	1,441	1,138	0,303	3
2	+	2,824	2,235	0,589	5

Discussion

Using surgical suture decrease risk of inflammatory reaction, rejection or systemic response. Frantisek et al found that 72 patients underwent FOA using vicryl suture did not developed rejection or systemic response [9]. In line in our study, all patient shown no rejection / systemic response and positive bony union from CT evaluation.

Conclusions

Using surgical suture shown effective and efficient in line with today's healthcare environment that requires hospitals to continue to maintain quality standards while lowering material costs to remain financially viable.

References

- [1] Wilkie AO. "Epidemiology and genetics of craniosynostosis". *Am J Med Genet*, vol 90, no 1, pp 82-84, 2000
- [2] P Mark R, A Muhammad M, In: Youmans & Winn Neurological Surgery (Ed), *Molecular Genetics and Principles of Craniosynostosis*, vol. 3, Elsevier, Philadelphia, p.1554, 2017
- [3] Seal, Shane K. F., et al. "The Cranial Orbital Buttress Technique for Nonsyndromic Unicoronal and Metopic Craniosynostosis." *Neurosurgical Focus*, vol. 38, no. 5, 27 Feb. 2015, pp. 1–8., doi:10.3171/2015.2.focus14844.
- [4] Kumar CR, Sood S, Ham S. "Complications of bioresorbable fixation systems in pediatric neurosurgery". *Childs Nerv Syst*. 2005; 21(3): 205–210, doi: 10.1007/s00381-004-0997-0, indexed in Pubmed: 15278386.
- [5] Losken A, Williams J, Burstein F, et al. "Outcome Analysis for Correction of Single Suture Craniosynostosis Using Resorbable Fixation". *Journal of Craniofacial Surgery*. 2001; 12(5): 451–455, doi: 10.1097/00001665-200109000-00009.
- [6] Pietrzak WS, Verstynen ML, Sarver DR. "Bioabsorbable fixation devices: status for the craniomaxillofacial surgeon". *J Craniofac Surg*. 1997; 8(2): 92–96, indexed in Pubmed: 10332273.
- [7] Tessier P. "Total facial osteotomy. Crouzon's syndrome, Apert's syndrome: oxycephaly, scaphocephaly, turriccephaly". *Ann Chir Plast* 12:273–286, 1967 (Fr)
- [8] Marsh JL, Gado M. "The longitudinal orbital CT projection: a versatile image for orbital assessment". *Plast Reconstr Surg* 1983; 71:308–317.
- [9] Horn F, Kiliiris E, Pinzon J, Tsolakis I, Kabat, Petrik M, Kuniakova D, "Absorbable sutures for the achievement of stable osteosynthesis in surgery for craniosynostosis" *Polis Journal of Neurology and Neurosurgery*, vol 53, no 2, pp 150-155, 2019