

Improving Motoric Outcome after Early Craniectomy in Patient with Open Depressed Fracture Involving Motoric Cortex Area : A Case Report

Syekh Ahmad Arafat Husain¹, Tommy Rizky Hutagalung¹, Nindi Lizen¹, Mahyudanil¹

¹Department of Neurosurgery, Universitas Sumatera Utara, Medan, Indonesia

Abstract

Introduction : Traumatic brain injury (TBI) remains a major public health problem worldwide. It is a leading cause of mortality and disability across the globe. Brain swelling and intracranial hypertension are well-recognized secondary insults associated with increased mortality and poorer outcomes. In majority of head injury cases, the incidence of depressed skull fracture is also increasing. When this situation involving in motoric cortex area, it can cause limb weakness and devastating effect.

Case Report : We reported a 21 year old male patient came with complaints of decreased consciousness due to a motorcycle accident. On motoric examination, hemiplegia was found in the left limb. There was a open wound in the right fronto-parietal region, Head CT Scan revealed a depressed fracture in the right fronto-parietal region and multiple contusions on the right frontal. Craniectomy procedures was performed. Post operatively there is an improvement in patient consciousness and motoric outcome.

Discussion : Open depressed fracture is one of the most common traumatic brain injury (TBI). Prevent infection and saving traumatic penumbra is the main target of surgery in this case. The pathophysiological changes in the traumatic penumbra are dynamic processes, the development and outcome of TBI depends greatly on the progression of tissue damage in the traumatic penumbras. Early clinical treatment can effectively rescue the tissue which has the potential to recover and hinder the progression of secondary injury

Conclusion : Traumatic brain injury (TBI) has high morbidity and mortality in worldwide. Time dependent progression has provided a window of opportunity to take interventional action and reduce secondary injury after TBI. Motoric outcome can improve with early management.

Keyword : Traumatic Brain Injury, Depressed Fracture, Motoric Outcome, Penumbra

Introduction

Traumatic brain injury (TBI) remains a major public health problem worldwide. It is a leading cause of mortality and disability across the globe. Brain swelling and intracranial hypertension are well-recognized secondary insults associated with increased mortality and poorer outcomes. Traumatic brain injury can cause brain tissue injury which is classified as direct injury and extension of late injury (secondary injury). Primary brain injury is caused by mechanical force which causing injury on brain directly after trauma (blast, laceration, bruising, hematoma, and bleeding).[1]

Sixty-nine million individuals worldwide are estimated to sustain a TBI each year. The proportion of TBIs resulting from road traffic collisions was greatest in Africa and Southeast

*Corresponding author at: Department of Neurosurgery, Universitas Sumatera Utara, Medan, Indonesia

Asia (both 56%) and lowest in North America (25%). The incidence of from road traffic collisions was similar in Southeast Asia (1.5% of the population per year) and Europe (1.2%). Low and middle income countries experience nearly 3 times more cases of TBI proportionally than The high income countries. In Indonesia, TBI is caused of disability in daily activity. The incident rate became increased every year from 8.2% in 2013 to be 9.2% in 2018. The highest prevalence rate of TBI was on age over 15–24 years old (12.2%), male (11%) and rural area (9.4%). Road traffic accident still counted high proportion (31.4%) but tend to low according to the previous report in year 2013 (42.8%). Riding a motor cycle is high caused TBI (72.7%) and male (80.9%).[1] [2]

In majority of head injury cases, the incidence of depressed skull fracture is increasing. Depressed fractures of the skull and facial fractures occur in less than 10% of all head injuries, but should therefore tip off the clinician to look out for intracranial damage . In a depressed skull fracture, the major bone depression can occur at the interface of fracture. Majority of depressed skull fractures occur over frontoparietal region as bone is comparatively thin and prone to trauma. When the open depressed fracture involving in motoric cortex area, it can cause limb weakness and devastating effect. Early and excellent management of these cases is still a challenge for health professionals, especially neurosurgeons. [3] [4]

This paper contains a case report regarding the incidence of open depressed fracture as one of the type of traumatic brain injury. In this case report, the areas involved in fracture is the primary motor area, so that the patient comes with a total weakness of the left limb and loss of consciousness.

Case Report

We reported a 21 year old male patient came with complaints of decreased consciousness, experienced by the patient since 6 hours before admitted to the hospital due to a motorcycle accident. The patient was admitted with consciousness GCS 13 (E4M5V4), 3mm isocor pupil with positive light reflex. On motoric examination, hemiplegia was found in the left limb. There was an open wound in the right fronto-parietal region, the size of the wound was 10x1cm with the base of the wound was bone, there was a palpable crepitus in the torn wound area. Based on the results of the non-contrast Head CT scan, there was a depressed fracture in the right fronto-parietal region, with the bone segment pressing the motor cortex area of the right brain. In the brain window image, there is multiple contusions and intraparenchymal bleeding on the right frontal.

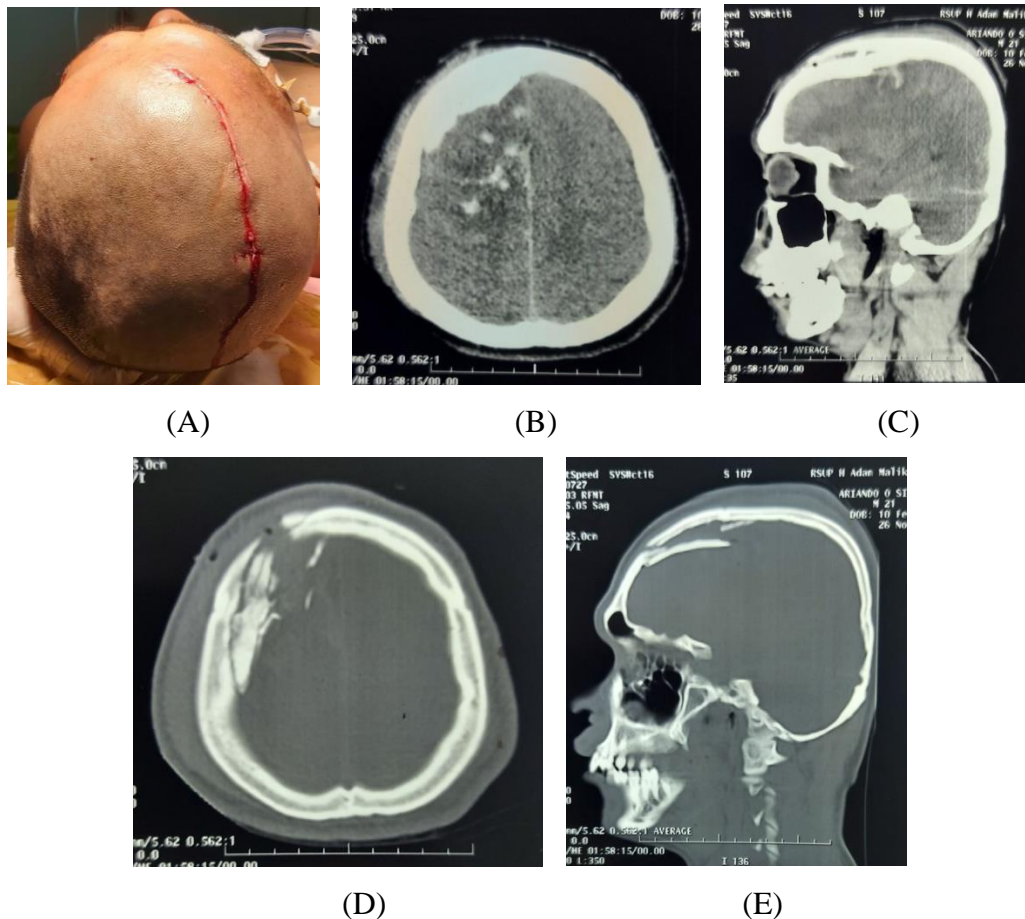


Figure 1. (A) Clinical features of the wound (B) (C) Non contrast head CTscan brain window axial and sagittal view shows multiple contusion on right frontal (D)(E) Non contrast head CTscan bone window axial and sagittal view shows depressed fracture on the right fronto-parietal region

Based on the physical examination and head CT scan results, the diagnosis of open depressed fracture in the right fronto-parietal region was established. It was decided to perform a debridement craniectomy on the patient. During the operation, the wound was washed using normal saline and povidone iodine, then the fracture boundaries was identified. After identification of the fracture boundary, there is a fragment of bone fracture that pierces to the brain parenchyma in the right motor cortex area. This fracture causes tears in the duramater and lacerated parenchyma of the right brain. Bone fracture was evacuated, duraplasty was done and bleeding control were performed. The wound is closed with stitches layer by layer.

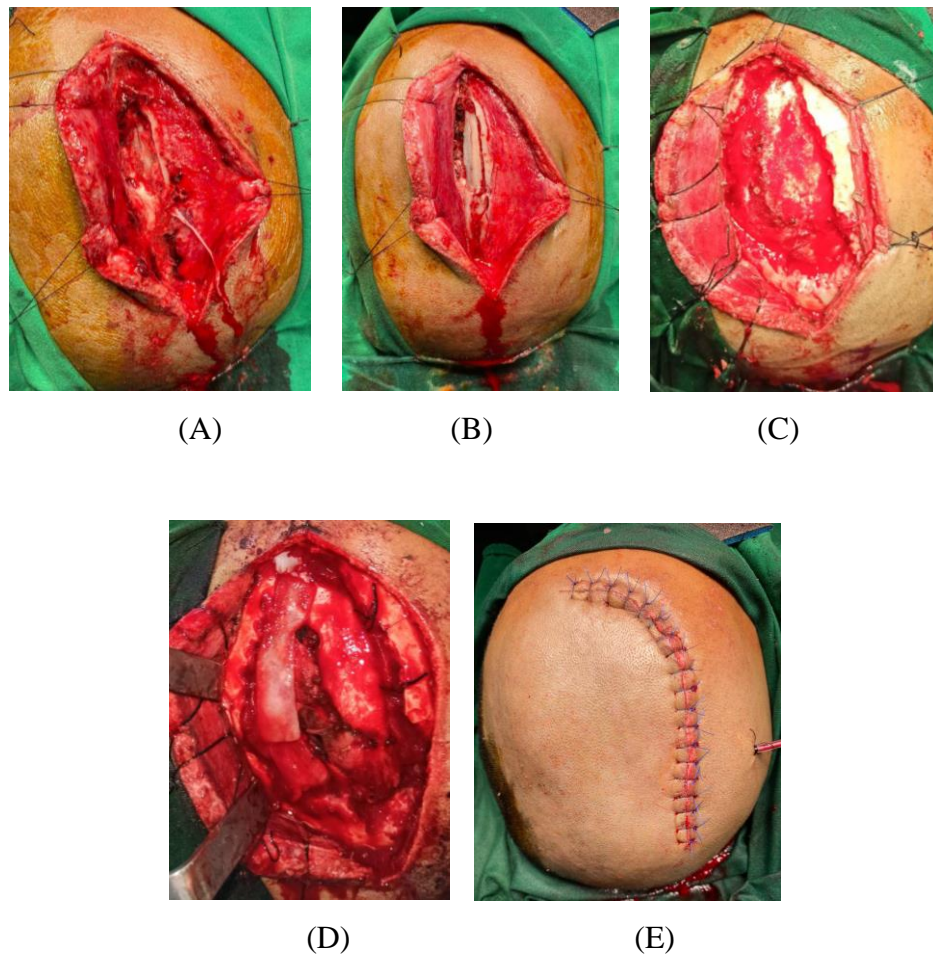


Figure 2. (A) Wound explore (B) Depressed Segment fracture penetrating brain (C) Tear in duramater and parenchym (D) Duraplasty (E) Wound Closing

Post operatively, the patient's condition improved with consciousness GCS 15 and increased motoric strength to 2 (two). The patient was scheduled for physiotherapy and was sent home for control to the polyclinic on the 10th day postoperative.

Discussion

Traumatic brain injury (TBI) is one of the most common neurologic disorders causing disability. In patients with TBI, motor weakness is one of the main sequelae, although motor weakness has the characteristics of lower incidence, less severity, and better prognosis compared with cognitive or behavior problems. Several injury mechanisms are known to cause motor weakness in TBI are Diffuse axonal Injury, deep cerebral hemorrhage, focal cortical contusion, transtentorial herniation, and hypoxic ischemic injury. [5]

Traumatic brain injury (TBI) generally results from mechanical impact or acceleration-deceleration insults that cause skull fractures, compression of cerebral tissues, and tearing of white and gray matter and subsequent hemorrhage. TBI can lead to a spectrum of

histopathological changes, including hemorrhagic contusion, intracerebral hemorrhage, subarachnoid hemorrhage, and widespread white matter damage. Thus, histological damage after TBI can be both focal and diffuse. The primary insult initiates a wide range of secondary injury mechanisms that critically participate in the pathogenesis of TBI. In conditions of severe TBI, reductions in cerebral blood flow (CBF) have been reported to reach ischemic levels. Thus, cerebral ischemia is discussed as one secondary injury mechanism that may participate in brain trauma. [6] [7]

Regional blood flow studies using xenon-enhanced CT (Xe/CT) demonstrated lower-than-ischemic threshold regional cerebral blood flow (CBF) within and around the contused tissues, raising the question of an ischemic state. This led to the concept of the pericontusional “penumbra,” analogous to the potentially salvageable zone bordering cerebral infarcts. [8]

Ischemia has been considered a major pathophysiological component of traumatic brain injury (TBI), an assumption that began with the classic post-mortem studies in which post-traumatic histopathological changes appear similar to those seen after classic ischemia. Subsequent in vivo studies, using global CBF and arteriovenous (AV) differences of oxygen concentration measurements, largely failed to detect appreciable ischemia. It was suggested that the “elusive” ischemic event likely occurred immediately after the traumatic event, before timing of most clinical studies. [9] The low CBF values in the pericontusional hypodense regions suggest that these areas were most likely progressing toward necrosis after TBI. Although the pericontusional region acutely appears unaffected on MRI and CT imaging, the metabolic information at the time studied by PET reveals that this region shows evidence of progressive, centrifugal compromise. [10]

Clinical improvement and function after head trauma is very dependent on many things. Recovery of neuron function involves three distinct phases. First, reversal of diaschisis and activation of cell repair, second, functional cell plasticity, that is, changing the properties of existing neuronal pathways, and third, neuroanatomical plasticity leading to the formation of new connections, Recovery of neurological function is dynamic and multifactorial, and dependent on the severity of ischemia. Hence the time of onset and location of various recovery processes will vary accordingly. Recovery of the penumbral tissue depends on the extent of the cellular stress imposed by the repetitive depolarizations occurring for several hours after onset of ischemia, as well as by edema and inflammation. [11]

In the case we presented there was an improvement in motor function of the patient with TBI open depressed fracture in the right motor cortex area. This may be due to the early treatment of the brain injury that occurred, so that the damage to the brain area did not continue

and the penumbra was saved. It is hoped that in follow-up patient control motor function will improve.

Conclusion

Traumatic brain injury (TBI) has high morbidity and mortality in worldwide. The pathophysiological changes in the traumatic penumbra are dynamic processes, the development and outcome of TBI depends greatly on the progression of tissue damage in the traumatic penumbras. Time dependent progression has provided a window of opportunity to take interventional action and reduce secondary injury after TBI. Early clinical treatment can effectively rescue the tissue which has the potential to recover and hinder the progression of secondary injury.

References

- [1] Michael C. Dewan et al. Estimating the global incidence of traumatic brain injury. *J Neurosurg* 130:1080–1097, 2019
- [2] Mahyudanil M, Bajamal AH, Sembiring RJ, Dharmajaya R. The Effect of Progesterone Therapy in Severe Traumatic Brain Injury Patients on Serum Levels of s-100 β , Interleukin 6, and Aquaporin-4. *Open Access Maced J Med Sci.* 2020 May 01; 8(B):236-244.
- [3] Ali Asmat Syed, Anjum Arshad , Khatoon Abida , Sardha Minakshi. Paraperesis: a rare complication after depressed skull fracture. 2011. *Pan African Medical Journal.* ISSN: 1937- 8688
- [4] Shakeel Ahmad, Ali Afzal, Lal Rehman , Farrukh Javed. Impact of depressed skull fracture surgery on outcome of head injury patients. *Pak J Med Sci* January - February 2018 Vol. 34 No. 1
- [5] Vlodaysky E, Palzur E, Feinsod M, Soustiel JF. Evaluation of the apoptosis-related proteins of the BCL-2 family in the traumatic penumbra area of the rat model of cerebral contusion, treated by hyperbaric oxygen therapy: a quantitative immunohistochemical study. *Acta Neuropathol* 2005; 110: 120-126.
- [6] Beaumont, A., and Gennarelli, T. (2006). CT prediction of contusion evolution after closed head injury: the role of pericontusional edema. *Acta Neurochir. Suppl*, 96, 30–32.
- [7] von Oettingen, G., Bergholt, B., Gyldensted, C., and Astrup, J. (2002). Blood flow and ischemia within traumatic cerebral contusions. *Neurosurgery* 50, 781–790.

- [8] Yu, I., Inaji, M., Maeda, J., Okauchi, T., Nariai, T., Ohno, K., Higuchi, M., and Suhara, T. (2010). Glial cell-mediated deterioration and repair of the nervous system after traumatic brain injury in a rat model as assessed by positron emission tomography. *J. Neurotrauma* 27,1463–1475.
- [9] Cunningham, A.S., Salvador, R., Coles, J.P., Chatfield, D.A., Bradley, P.G., Johnston, A.J., Steiner, L.A., Fryer, T.D., Aigbirhio, F.I., Smielewski, P., Williams, G.B., Carpenter, T.A., Gillard, J.H., Pickard, J.D., and Menon, D.K. (2005). Physiological thresholds for irreversible tissue damage in contusional regions following traumatic brain injury. *Brain* 128, 1931–1942.
- [10] Will B, Galani R, Kelche C, Rosenzweig MR: Recovery from brain injury in animals: relative efficacy of environmental enrichment, physical exercise or formal training (1990–2002). *Prog Neurobiol* 2004, 72:167-182.
- [11] Liu, Y., and Rouiller, E. M. (1999). Mechanisms of recovery of dexterity following unilateral lesion of the sensorimotor cortex in adult monkeys. *Exp. Brain Res.* 128, 149–159.