

## Overview of Patients with Metastatic Brain Tumors from Breast Cancer at H. Adam Malik Hospital, Medan in 2017-2021

Fahmi Rasyid<sup>1</sup>, Dhyka Alloyna<sup>1</sup>, Kamal Basri<sup>2</sup>

<sup>1</sup>Department of Neurosurgery, Faculty of Medicine, Universitas Sumatera Utara, Medan, Indonesia

<sup>2</sup>Department of General Surgery, Faculty of Medicine, Universitas Sumatera Utara, Medan, Indonesia

### Abstract

**Introduction:** Breast cancer is one of the most common causes of a metastatic brain tumor. Approximately 10%-16% of patients with breast cancer develop brain metastases during the course of their disease. Current case management guidelines for patients with metastatic brain tumors from breast cancer are radiotherapy to the entire brain, with or without surgical resection, or stereotactic radiosurgery.

**Method:** The study recorded from 78 patients with breast cancer brain metastases at RSUP HAM Medan between 2017 and 2021. Data were collected from SIRS RSUP HAM Medan. Data related to clinicopathology were collected from medical records, including demographic characteristics, tumor characteristics, biomarker status, recurrence of metastatic brain tumors based on Magnetic Resonance Imaging. ER and PR status were determined by immunohistochemical examination. the intensity of the HER2 3+ immunohistochemical staining was considered positive

**Result:** The mean age at breast cancer diagnosis was 46 years (range: 24-73 years). Most patients had invasive ductal histology (n=73, 94%). In addition, 56% of patients had 68% of patients (n=53) positive axillary lymph nodes. Total of 56% of tumors were ER negative (ER-; n=44), 62% were PR negative (n=48), and 44% were HER2-positive (HER2+; n= 34).

**Discussion:** In the current study, HER2 status was a strong predictor of survival outcome after brain metastases. Patients with HER2-positive characteristics had a longer life expectancy than patients with HER2-negative disease. Considering the intracranial antitumor effect of anti-HER2 therapy, it is important to establish HER2 status not only in primary tumors but also in brain metastases to aid in consideration of the choice of therapeutic modality

**Conclusion:** This study showed that younger age, brain metastases from solitary breast cancer, and HER2 positive from breast tumors were independent predictors of better survival in patients with breast cancer brain metastases

**Keyword:** breast cancer, brain metastasis, hormonal therapy

### Introduction

The incidence of breast cancer based on Globocan in 2018, reached 2,088,849 cases (11.6%), with a mortality rate of 626,679 cases (6.6%). The highest incidence of breast cancer occurred in Asia with 43.6% (911,014 new cases of breast cancer), 137,514 cases of which occurred in Asia Pacific with a mortality rate of 50,935 cases. Data in Indonesia shows that the highest incidence of cancer is breast cancer, which is 42.1 per 100,000 population with an average death rate of 17 per 100,000 population. Currently,

Corresponding author at: Department of Neurosurgery, Faculty of Medicine, Universitas Sumatera Utara, Medan, Indonesia

breast cancer therapy is surgery, chemotherapy, radiation, hormonal therapy, targeted therapy, and immunotherapy, but there are still problems in the form of recurrence and resistance to therapy.[1]

Breast cancer is one of the most common causes of a metastatic brain tumor. Approximately 10%-16% of patients with breast cancer develop brain metastases during the course of their disease. Recently, an increasing incidence of brain metastases (range 25%-34%) has been observed in the global community. This trend may be attributed to the increased awareness regarding the occurrence of brain metastases by both patients and clinicians, the increased use of more sensitive neuroimaging techniques, and the development of more effective systemic therapies, particularly anti-HER2 therapy, leading to better survival.[2]

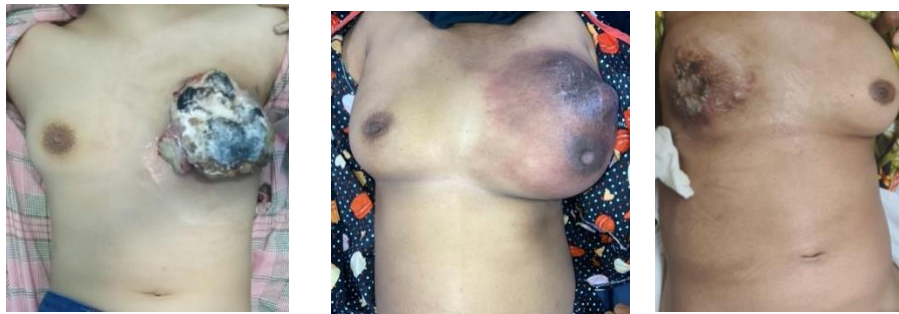Current case management guidelines for patients with metastatic brain tumors from breast cancer are radiotherapy to the entire brain, with or without surgical resection, or stereotactic radiosurgery. In addition, systemic therapy efforts including chemotherapy can also be given. After the occurrence of a metastatic brain tumor, the patient's prognosis generally tends to be poor, with survival rates reaching only 1 and 2 years in 2%-20% of cases, respectively. Clinical outcomes depend on many factors related to the patient, the course of the disease, and the patient's treatment regimen [3].

Hormone receptor ([HR]; estrogen receptor [ER], progesterone receptor [PR]) and HER2 expression serve as predictors of response to hormone-targeted therapy and HER2, respectively. In daily clinical practice, the assessment of these predictive and prognostic factors is carried out mainly in the case of breast tumors, and this examination is also performed to select the treatment for metastatic disease; however, distant metastases, particularly brain metastases, usually develop years after the initial diagnosis of breast cancer, often after multiple therapeutic interventions.[4] Recent studies have shown varying degrees of discrepancy in ER, PR, and HER2 expression between primary and metastatic disease, but little progress has been made. there is about the extent and sometimes inappropriate clinical implications of the development of metastatic brain tumors from breast cancer.[5]

## **Method**

The study was a descriptive study with a retrospective cohort design in which the researchers identified 78 patients with breast cancer brain metastases (either for diagnostic purposes or for therapeutic purposes at RSUP HAM Medan between 2017 and 2021. Data were collected from SIRS RSUP HAM Medan. Data related to clinicopathology were collected from medical records, including demographic

characteristics, tumor characteristics, biomarker status, recurrence of metastatic brain tumors based on Magnetic Resonance Imaging (MRI) examination, and data on therapeutic regimens in cases of brain metastases of breast cancer. ER and PR status were determined by immunohistochemical examination. the intensity of the HER2 3+ immunohistochemical staining was considered positive.



**Figure 1.** Data collection of Patients with Breast Ca at RSUP HAM Medan

## Result

This study directed at the demographic characteristics of 78 patients diagnosed with brain metastases from breast cancer from 2017 to 2021 at the Department of Neurosurgery, H. Adam Malik Hospital Medan. Patient and tumor characteristics are presented in Table 1. The mean age at breast cancer diagnosis was 46 years (range: 24-73 years). Most patients had invasive ductal histology (n=73, 94%). In addition, 56% of patients had T3 (n=34) T4 disease in 56% of patients (n=44) and 68% of patients (n=53) had positive axillary lymph nodes. Among patients with known HR and HER2 status, a total of 56% of tumors were ER negative (ER-; n=44), 62% were PR negative (n=48), and 44% were HER2-positive (HER2+; n= 34). With regard to the four subtypes formed by the combined values of HR and HER2 status, 21% (n=16) of tumors were HR+HER2+, 27% (n=21) were HR+HER2-, 23% (n=18) were HR+/ HER2-, and 28% (n=23) were triple negative (TN).

**Table 1.** Patient and tumor characteristics

Characteristic	Patient	
	n	%
Age	46 years (Min-Max: 24-73 years)	
<b>Tumor Size</b>		
T1	0	0
T2	0	0
T3	34	44
T4	44	56
<b>Histology Examination</b>		
Ductal	73	94
Lobular	2	2

Mammary	3	5
<b>Lymph Node</b>		
Negative	25	32
Positive	53	68
<b>ER</b>		
Positive	34	44
Negative	44	56
<b>PR</b>		
Positive	30	38
Negative	48	62
<b>HER2</b>		
Positive	34	44
Negative	44	56
<b>Subtype</b>		
HR+/HER2+	16	21
HR+/HER2-	21	27
HR-/HER2+	18	23
<i>Triple negative</i>	23	28
<b>First recurrence</b>		
Brain	40	52
Other	38	48
<b>Brain Metastasis</b>		
Solitary	18	23
Multiple	60	77

## Discussion

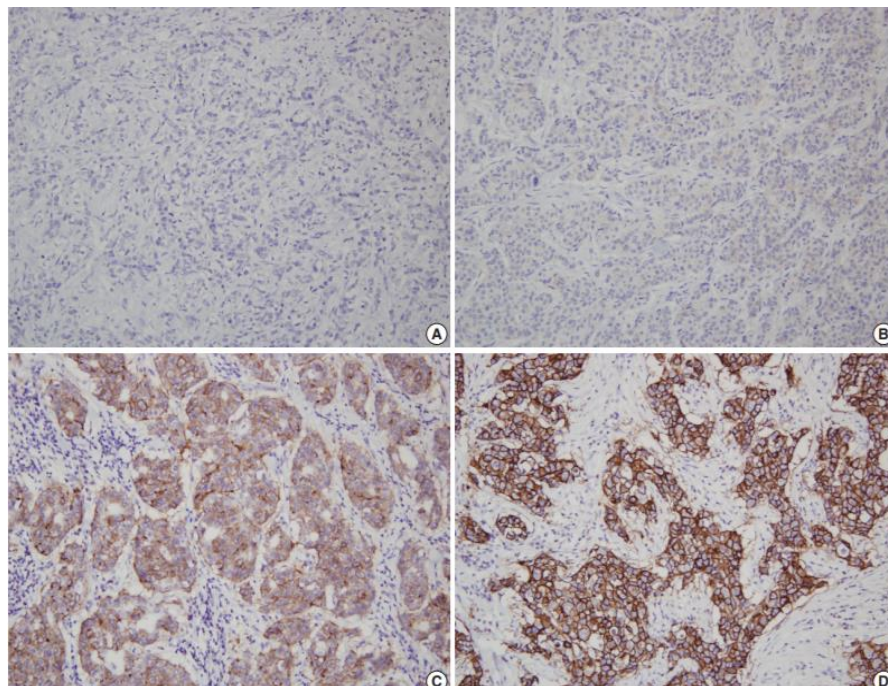
In this study conducted on 78 breast cancer patients with histologically confirmed brain metastases, consistent with previous studies, the investigators found that most of the patients had high grade tumors i.e. grade 3 by 34% and T4 by 44% with nodal positive status (68. %) at the time of breast cancer diagnosis. Among these patients, 60% were HR negative, 44% were HER2-positive, and 28% were triple negative. One study reported the characteristics of 11,011 women diagnosed with breast cancer between 1997 and 2012 who had data on HR and HER2 status. The study reported that among the cohort of breast cancer patients, 26% were HR negative, 17% were HER2-positive, and 20% were triple negative [6]. Consequently, the proportion of HR-negative, HER2-positive, and triple negative tumors recorded in patients with breast cancer who had brain metastases were significantly higher than the group of breast cancer patients excluded. The results of this study are in accordance with the results of other studies and support the statement that negative HR status, HER2 positive, and triple negative are risk factors for breast cancer brain metastases.[7]

Another study also reported an overall median survival of 4 months in a study of 101 patients with breast cancer brain metastases. Another study also reported a median survival of 6.8 months in a cohort of 420 patients diagnosed with brain metastases of breast cancer between 1994 and 2004. The explanation for this better survival can be explained and attributed to more sensitive imaging techniques and the use of advanced

imaging techniques. neurosurgical, radiosurgical, and systemic treatment modalities are more effective. [8]

It should be noted that compared to other studies, the investigators found a much higher proportion of patients in which the patient had only one brain lesion, and all patients underwent brain metastatic craniotomy. It is known that achieving local control in the brain increases survival.[9] Two randomized experimental studies have shown that in patients with brain metastases of breast cancer, treatment with surgical resection plus radiotherapy leads to longer survival than radiotherapy alone. In one study, a median superior survival of 19 months was reported in a group of metastatic brain tumors from breast cancer by craniotomy performed in 209 patients who were included after the diagnosis of brain metastases.[10]

In the current study, investigators found that apart from patient age and number of brain metastases, HER2 status was a strong predictor of survival outcome after brain metastases. Patients with HER2-positive characteristics had a longer life expectancy than patients with HER2-negative disease (18 versus 11 months;  $p=0.02$ ).[11] This observation is consistent with a recent study examining the effect of HER2 expression on patient outcomes after diagnosis of brain metastases. In a cohort of 60 patients treated with stereotactic radiosurgery, another study demonstrated an extended 1-year survival rate in HER2-positive patients treated with trastuzumab compared with similar patients with HER2-negative disease (78% vs 55%;  $p=0.02$ ).[12]



**Figure 2.** Representative description of HER2 expression in breast cancer immunohistochemistry (A). HER negative, (B). HER+, (C). HER2+, (D). HER3+[12]

Another retrospective cohort study of 108 patients with breast cancer brain metastases reported significantly better median survival in patients with HER2-positive tumors compared with patients with HER2-negative tumors (22 months compared with 9 months;  $p=0.002$  ). The investigators found that HER2-positive patients who received HER2-targeted therapy had a median survival of 21 months, which is significantly longer than the survival of HER2-negative patients (11 months;  $p=0.09$ ) and patients with HER2-positive characteristics, but did not receive HER2-targeted therapy (7 months;  $p = 0.003$ ) after brain metastases. [13]

The results of this study suggest that survival is not influenced by tumor biologic properties associated with HER2 but largely reflects better disease control associated with anti-HER2 therapy. How anti-HER2 therapy prolongs survival in patients with HER2-positive disease is not fully understood. Previously, it was believed that survival rate was influenced by antitumor activity in the extracranial area affected by trastuzumab, the most commonly used anti-HER2 antibody, as this drug cannot cross the blood-brain barrier effectively. Recent studies have shown that trastuzumab may also play a role in the progression of intracranial tumors in patients with brain metastases from breast cancer. In animal model studies, 0.5 mm brain metastases were associated with disruption of endothelial cells, impaired interactions between pericytes and glia, and disruption of the blood-brain barrier in the peritumoral vessels [14]. Whole-brain radiotherapy, which is the standard of care in this case, for patients with brain metastases, it has been shown to penetrate the blood-brain barrier and facilitate transport of therapeutic agents to the brain.

Studies have reported a five- to six-fold increase in cerebrospinal fluid levels of trastuzumab after radiotherapy treatment in patients with brain metastases of breast cancer. Consistent with these findings, another study demonstrated a significantly better survival rate for the development of intracranial tumors in patients treated with trastuzumab after being diagnosed with brain metastases. Lapatinib is a tyrosine kinase inhibitor directed against epidermal growth factor receptor (EGFR) and HER2. This compound has a much lower molecular weight than trastuzumab (943 Da) compared to 148,000 Da) and it has been reported by various studies that it can cross the blood-brain barrier [11],[13]. A phase II study, reported that 66% of patients with brain metastases previously untreated HER2-positive metastatic breast cancer responded well to combination therapy with lapatinib plus capecitabine.

Considering the intracranial antitumor effect of anti-HER2 therapy, it is important to establish HER2 status not only in primary tumors but also in brain metastases to aid in consideration of the choice of therapeutic modality. In examining biomarkers, investigators found a correlation between the HER2 status of primary and metastatic brain

tumors (97% as evidenced by immunohistochemistry [IHC] and FISH; 35 of 36 pairs of breast and brain tumors). The sample studied was only from patients with HER2-positive breast cancer who, after being treated with neoadjuvant chemotherapy and mastectomy, developed brain metastases with HER2-negative characteristics. which in this case is brain metastases. Overall, this study demonstrates that HER2 examination of primary breast tumors is a predictor of HER2 status in brain metastases, and brain lesion biopsies are only performed for the purpose of determining HER2 status, which is often of little importance [14],[15],[16]

Breast cancer is a molecular heterogeneous disease, with genetic mutations that are not cytogenetically related and are found unequally in half of all breast tumors. A progenitor mutation that has the potential to metastasize may be present as a fraction in the primary tumor that cannot be sampled or detected. During disease progression, these specialized genes evolve, develop, and form metastatic deposits that are genetically distinct from most cells in the primary tumor.[17]

Previous conventional treatments such as chemotherapy can also cause changes in HR status. The prognostic impact of the discrepancy between receptor expression in primary and metastatic tumors is also unclear.[18] In another study, 4 of 18 patients with HR-positive primary tumors changed to HR-negative status for those with brain metastases, whereas 7 of 17 patients with HR-negative primary tumors changed to HR-positive status in brain metastases; loss or gain of HR expression in brain metastases does not appear to have a significant effect on survival after patients are diagnosed with breast cancer brain metastases.[19] Further studies with a larger number of patients are needed to look at more diverse characteristics with expandable variables.

## **Conclusion**

This study showed that younger age, brain metastases from solitary breast cancer, and HER2 positive from breast tumors were independent predictors of better survival in patients with breast cancer brain metastases. HER2 expression was correlated with primary tumor and recurrent brain metastases, whereas changes in ER and PR status were observed in most patients without exception. The results of this study are important for consideration of effective treatment options for patients with brain metastases of breast cancer.

## References

- [1]. Sung H, Ferlay J, Siegel RL, et al. Global Cancer Statistics 2020 : GLOBOCAN Estimates of Incidence and Mortality Worldwide for 36 Cancers in 185 Countries. *Ca Cancer*. 2021;71(3):209-249. doi:10.3322/caac.21660
- [2]. Fecci PE, Champion CD, Hoj J, et al. The Evolving Modern Management of Brain Metastasis. *Clin Cancer Res*. 2019;2:1-11. doi:10.1158/1078-0432.CCR-18-1624
- [3]. Witzel I, Oliveira-ferrer L, Pantel K, Müller V, Wikman H. Breast cancer brain metastases : biology and new clinical perspectives. *Breast Cancer Res*. 2016:1-9. doi:10.1186/s13058-015-0665-1
- [4]. Martínez MT, Oltra SS, Peña-chilet M, et al. Breast Cancer in Very Young Patients in a Spanish Cohort : Age as an Independent Bad Prognostic Indicator. *Breast Cancer Res*. 2019;2:1-8. doi:10.1177/1178223419828766
- [5]. Keegan THM, Derouen MC, Press DJ, Kurian AW, Clarke CA. Occurrence of breast cancer subtypes in adolescent and young adult women. *Breast Cancer Res*. 2012;14(2):R55. doi:10.1186/bcr3156
- [6]. Yao Y, Cao M, Fang H, Xie J. Breast cancer in 30-year-old or younger patients : clinicopathologic characteristics and prognosis. *World J Surg Oncol*. 2015;3:1-4. doi:10.1186/s12957-015-0462-4
- [7]. Koniali L, Hadjisavvas A, Constantinidou A. Risk factors for breast cancer brain metastases : a systematic review. *Oncotarget*. 2020;11(6):650-669.
- [8]. Laakmann E, Witzel I, Neunhö T, et al. Characteristics and Clinical Outcome of Breast Cancer Patients with Asymptomatic Brain Metastases. *Cancer*. 2020:1-14.
- [9]. Bryan S, Witzel I, Borgmann K, Oliveira-ferrer L. Molecular Mechanisms Associated with Brain Metastases in HER2-Positive and Triple Negative Breast Cancers. *Cancer*. 2021:1-19.
- [10]. Chow L, Suen D, Ma KK, Kwong A. Identifying risk factors for brain metastasis in breast cancer patients : Implication for a vigorous surveillance program. *Asian J Surg*. 2015;38(4):220-223. doi:10.1016/j.asjsur.2015.03.003
- [11]. Hadjipanteli A, Doolan P, Constantinidou A. Breast Cancer Brain Metastasis : The Potential Role of MRI Beyond Current Clinical Applications. *Cancer Manag Res*. 2020;3:1-10.
- [12]. Anders C, Bedard PL, Oliveira M, et al. Tucatinib, Trastuzumab, and Capecitabine for HER2-Positive Metastatic Breast Cancer. *N Engl J Med*. 2020;3:597-609. doi:10.1056/NEJMoa1914609
- [13]. Lv Y, Du Y, Feng J. Understanding Patterns of Brain Metastasis in Triple-Negative Breast Cancer and Exploring Potential Therapeutic Targets. *Onco Ther*. 2021;3:1-8.
- [14]. Niikura N, Saji S, Tokuda Y, Iwata H. Brain Metastases in Breast Cancer. *Japan J Clin Oncol*. 2014;44(October):1133-1140. doi:10.1093/jjco/hyu156
- [15]. Witzel I, Laakmann E, Weide R, Neunho T, Wu R, Mu V. Treatment and outcomes of patients in the Brain Metastases in Breast Cancer Network Registry. *Eur J Cancer*. 2018;102:1-9. doi:10.1016/j.ejca.2018.07.004
- [16]. Wu S-G, Sun J-Y, Tong Q, Li F-Y, He Z-Y. Clinical features of brain metastases in breast cancer : an implication for hippocampal-sparing whole-brain radiation therapy. *Ther Clin Risk Manag*. 2016;3:1849-1853.
- [17]. Shen Q, Sahin A, Hess K, Suki D. Breast Cancer With Brain Metastases : Clinicopathologic Features , Survival , and Paired Biomarker Analysis. *Oncologist*. 2015;4:466-473.
- [18]. Brogi E, Murphy CG, Johnson ML, et al. Breast carcinoma with brain metastases : clinical analysis and immunoprofile on tissue microarrays. *Ann Oncol*. 2011;22(12):2597-2603. doi:10.1093/annonc/mdr022
- [19]. Sim H, Morris PG. Brain metastases in breast cancer. *Expert Rev Anticancer Ther*. 2013;14(2):0. doi:10.1586/14737140.2014.863468