

## Giant Size Pilocytic Astrocytoma in Pediatric Patient : A Case Report

Oktama Vegi Haryan<sup>1</sup>, Abdurahman Mousa Arsyad<sup>2</sup>, T Akmal Kausar<sup>3</sup>, Rais Fadhlan Siregar<sup>3</sup>,  
Syekh Ahmad Arafat Husain<sup>3</sup>

<sup>1</sup>Apprentice, Department of Neurosurgery, Faculty of Medicine, Universitas Sumatera Utara, Medan,  
Indonesia

<sup>2</sup>Neuropediatric Division, Department of Neurosurgery, Faculty of Medicine, Universitas Sumatera  
Utara, Medan, Indonesia

<sup>3</sup>Resident, Department of Neurosurgery, Faculty of Medicine, Universitas Sumatera Utara, Medan,  
Indonesia

### Abstract

**Introduction:** Pilocytic astrocytomas are the most common primary tumor in children and adolescents, accounting for approximately 15.6% of all brain tumors and 5.4% of all gliomas. The incidence of tumors substantially decreases with age and diagnosis in patients older than 50 years is less common. According to the Central Brain Tumor Registry of the United States (CBTRUS), its development is more common in the first two decades of life and there are few reports in the age group over 18 years.

**Case Report:** An 8-year-old girl was brought by her parents with complaints of loss of consciousness. This happened 2 days before admission to the hospital. The patient was prepared for craniotomy tumor removal. During the operation, the tumor specimen was sent to Anatomical Pathology for histopathological examination. The examination revealed calcified Rosenthal Fibers and eosinophilic granular bodies.

**Discussion :** Astrocytic tumors originate from neuroepithelial tissue and are grade I because of their well-defined and slow-growing nature. They are mostly found in infratentorial structures such as the cerebellum and in the midline of brain structures such as the optic nerve, hypothalamus, and brainstem. However, it can be found anywhere on the neuroaxis. Considered relatively rare in adults, there are few publications on the most efficient treatment methods and subsequent patient outcomes.

**Conclusion:** Pilocytic astrocytoma (PA) treated with complete or near complete tumor resection tends to have a better prognosis, recent studies recommend aggressive tumor resection without neurologic deficits.

**Keyword:** Pediatric Brain Tumor, Pilocytic Astrocytoma, Oncology, Neurosurgery

---

\*Corresponding author at: Department of Neurosurgery, Faculty of Medicine, Universitas Sumatera Utara, Medan, Indonesia

E-mail address: aanhsj@usu.ac.id

Copyright © AANHS J., Published by Talenta Publisher, ISSN: 2686-0848 ; DOI : 10.32734  
Journal Homepage: <http://aanhsj.usu.ac.id>

## Introduction

Primary brain and central nervous system tumors are the most prevalent and frequent neoplasm in children and adolescents aged 0 to 19 years. Brain and CNS tumors are the second leading cause of cancer-related deaths in children and adolescents aged 0 to 19 years old. Previous studies in several countries have reported the incidence rate of primary brain and CNS tumors in children and adolescent, ranged from 1.08 to 5.57 per 100,000 population. The incidence of brain tumor in pediatric patients has increased in the past decades, due to innovations in the imaging studies and the increase of benign form diagnoses.[1][2]

The incidence of pediatric CNS tumors worldwide varies with an average of 4 cases per 100,000 children. The highest occurrence is in the United States. Based on the study by Rictherova et al. in 2018, according to the age groups, the highest incidence is in adolescents aging 15-19 years with 6.38 per 100,000 children, followed by children aging under 1 year with 6.2 per 100,000 children. About 25-30% of tumors are in supratentorial localization, followed by the cerebellum (15-20%), brain stem (10-12%), pituitary and suprasellar region (10-15%), cranial nerves (6-7%), brain ventricles (5-6.4%), spinal cord (4.3-4.6%), and meningeal tumor (2.6-2.9%).[3][4]

The topographical features of brain tumors in infants are distinct from those of older children. First, the relationship of tumor location to the tentorium is reversed in young children when compared with children of older age groups. A summary of several large published series totaling 1252 cases indicates that in children <2 years of age at diagnosis, supratentorial tumors account for 63.8% of lesions and infratentorial tumors are found in 32.4%. If the age group is limited to children between birth and 2 months of age at diagnosis, the distribution is further biased toward the supratentorial compartment, with 74.7% of tumors being supratentorial and 17.9% being in the posterior fossa.[4][5][6]

Another unique feature of brain tumors of very young children is their relatively large size. These tumors frequently occupy a significant portion of the hemispheric volume. In one series from the Hospital for Sick Children in Toronto, the average maximal diameter of tumors in children <1 year of age at diagnosis was 4.6 cm, with most tumors measuring between 4 and 10 cm in largest diameter. [6][7]

Pilocytic astrocytomas are the most common primary tumors found in children and adolescents, with approximately 15.6% of all brain tumors and 5.4% of all gliomas. The incidence of these tumors substantially decreases with age and diagnosis in patients older than 50 years is rare. According to Central Brain Tumor Registry of the United

States (CBTRUS), its development is more common in the first two decades of life and there are a few reports in the age group above 18 years. Astrocytic tumors derive from neuroepithelial tissue and are grade I because of their well-circumscribed and slow-growing nature. They are mostly found in infratentorial structures such as the cerebellum and in midline brain structures such as the optic nerve, hypothalamus, and brain stem. However, it can be found anywhere on the neuroaxis. Considered relatively rare in adults, there are a few publications of the most efficient treatment methods and subsequent patient outcomes and pilocytic astrocytoma is associated with higher mortality in adult patients than in children and adolescents[6][7][8]. In this case report, we report the main characteristics of pilocytic astrocytomas for a better understanding of the diagnosis and treatment of these patients.

### **Case Report**

An 8-year-old girl was brought by her parents with complaints of loss of consciousness. This happened two days before he was admitted to the hospital, and this was slowly being complained of by the family. A history of headaches was found one week before admission to the hospital, the pain came and went. A history of seizures was found 3 years before admission to the hospital, and was given seizure medication by a pediatrician. At this time, the patient had no seizures. There was no history of vomiting, no history of blurred vision, a history of emotional disturbances found three days before admission to the hospital, where according to the patient's family he often became angry.

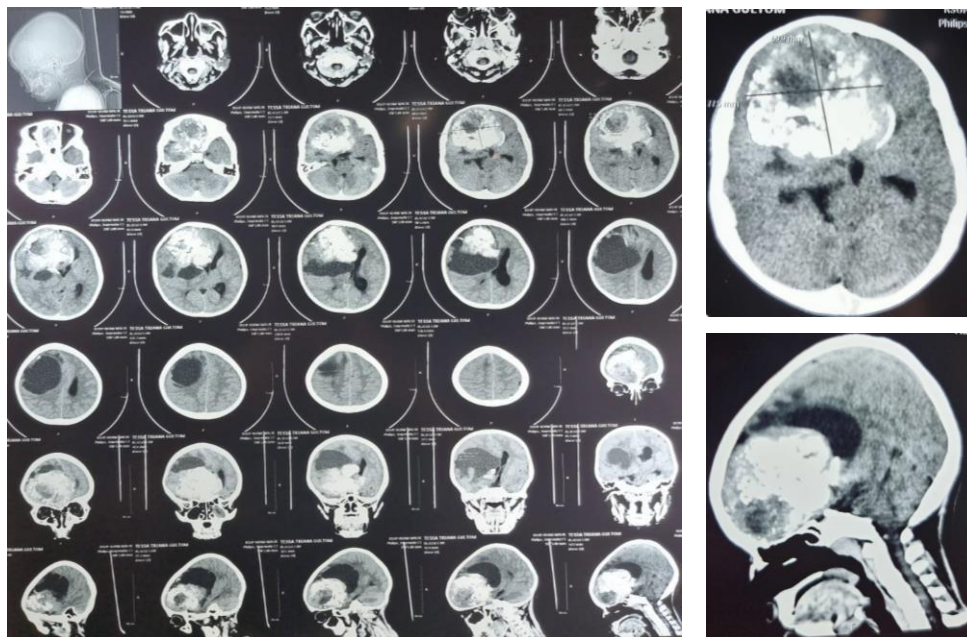
A history of memory impairment was found, the patient had difficulty remembering school lessons. There was no history of weak limbs, no history of weight loss, no history of fever, shortness of breath and cough. The patient previously went to Hardianus Samosir Hospital to receive treatment for 3 days and then was referred to H. Adam Malik Hospital, Medan. The patient's previous medical history was epilepsy, and a history of using drugs such as Valproic Acid, Phenytoin, Diazepam.

Regarding pregnancy history, the patient is the 3rd child of 4 siblings, pregnant woman at the age of 34 years, has never been sick during pregnancy. Mother regularly visits the midwife 5 times and has never had an ultrasound. Birth history The patient was born in a midwife at 9 months of gestation (quite months), immediately cried, no history of bluish discharge, no history of shortness of breath.

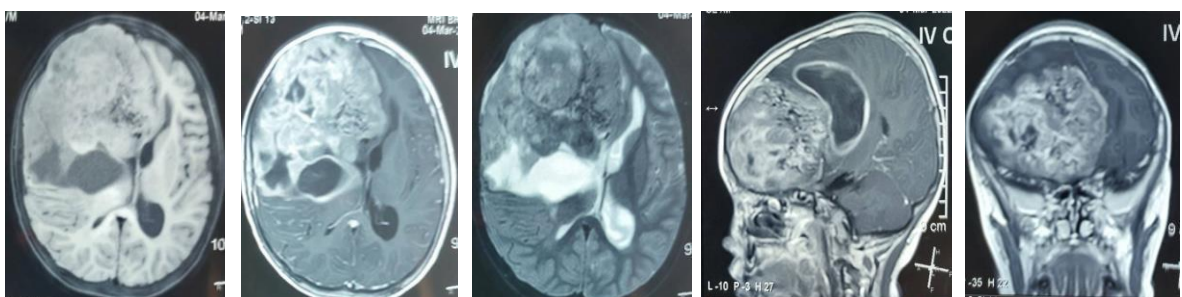
Physical examination showed vital signs where blood pressure was 110/90 mmHg, pulse rate was 99x/minute, respiratory rate was 24 x/minute and body

temperature was 37.2 C. The patient's eyes showed isochoral pupils, 3mm/3mm positive light reflex in the right and left eyes, the neck showed medial trachea, the lymph nodes were not palpable. Thorax is symmetrical, vesicular breath sounds are found in the right and left lungs, rhonki are not found, axilla shows no palpable lymph nodes, abdomen looks symmetrical, soepel, tympani, peristaltic are normal. Extremities and genitalia appear normal.

Neurological examination showed the level of consciousness GCS E3M5V3, the meningeal sign and cerebellar sign were not found, the motor appeared to be lateralized to the left while the sensory was difficult to assess. Positive physiological reflexes were found in normoreflexes, and Babinsky's pathological reflexes were found in the right extremity. The preoperative Non-contrast CT-Scan Head can be seen in Figure 1. Preoperative MRI with Intravenous Contrast can be seen in Figure 2.



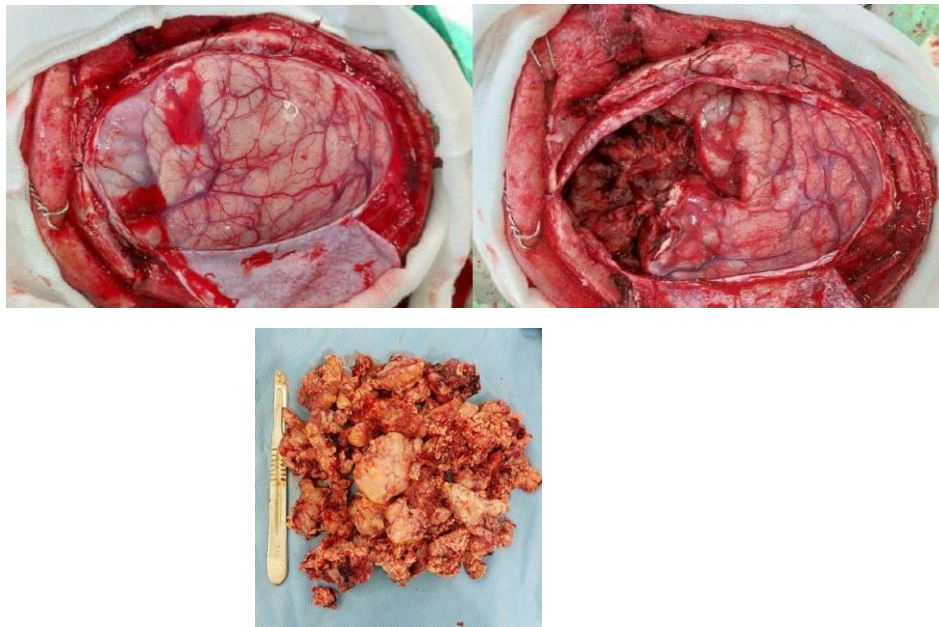
**Figure 1.** Preoperative Non-Contrast Head CT-Scan



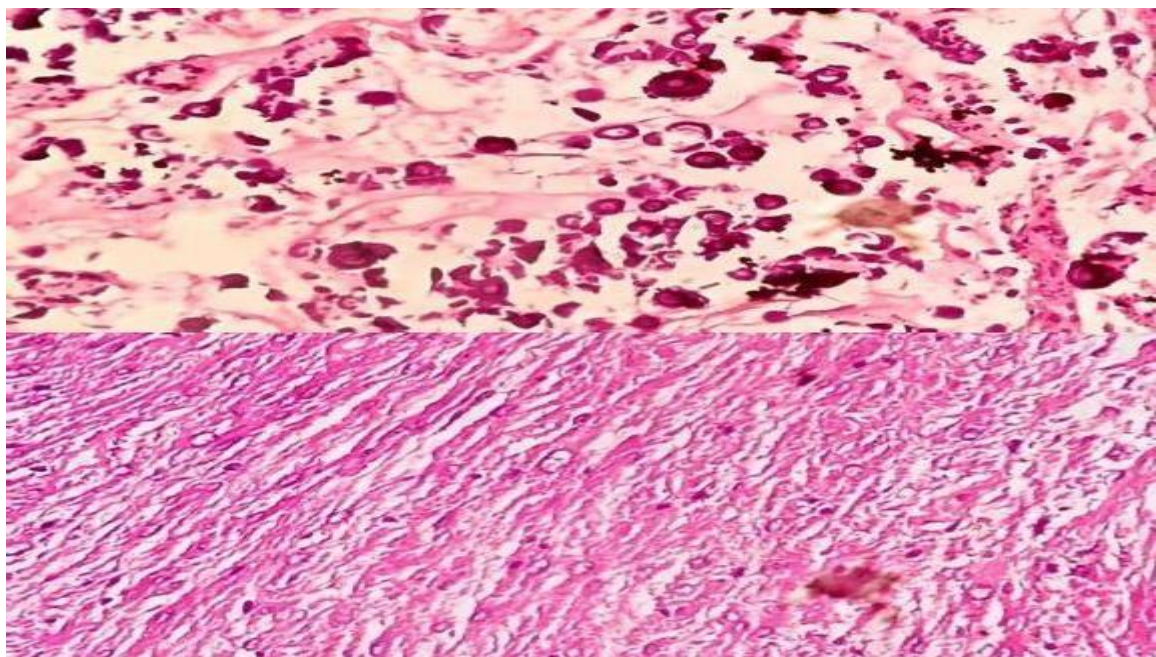
**Figure 2.** Preoperative MRI with IV Contrast

The patient was diagnosed with an intracranial tumor with suspicion of a Primitive Neuroectodermal Tumor (PNET) with differentially diagnosed a glioma tumor. The patient is then prepared for craniotomy tumor removal.

Intraoperative findings can be seen in in Figure 3. The specimen from the tumor was then sent to Pathology Anatomy for histopathological examination. The examination revealed calcified Rosenthal Fibers & eosinophilic granular bodies Figure 4.



**Figure 3.** Intraoperative findings



**Figure 4.** Histopathological examination : Rosenthal Fibers & Eosinophilic granular bodies

## Discussion

Primary brain and central nervous system tumors are the most prevalent and frequent neoplasm in children and adolescents aged 0 to 19 years. Brain and CNS tumors are the second leading cause of cancer-related deaths in children and adolescents aged 0 to 19 years old. Previous studies in several countries have reported the incidence rate of primary brain and CNS tumors in children and adolescent, ranged from 1.08 to 5.57 per 100,000 population. The incidence of brain tumor in pediatric patients has increased in the past decades, due to innovations in the imaging studies and the increase of benign form diagnoses. The clinical manifestations are variable in relation to the location, age, infiltrative or mass effect behaviour. It is estimated that the most common histologies are astrocytoma, medulloblastoma, and craniopharyngioma [9][10][11].

Pilocytic astrocytomas are the most common primary tumors found in children and adolescents, with approximately 15.6% of all brain tumors and 5.4% of all gliomas. The incidence of these tumors substantially decreases with age and diagnosis in patients older than 50 years is rare. According to Central Brain Tumor Registry of the United States (CBTRUS), its development is more common in the first two decades of life and there are a few reports in the age group above 18 years [12][13].

Astrocytic tumors derive from neuroepithelial tissue and are grade I because of their well-circumscribed and slow-growing nature. They are mostly found in infratentorial structures such as the cerebellum and in midline brain structures such as the optic nerve, hypothalamus, and brain stem. However, it can be found anywhere on the neuroaxis. Considered relatively rare in adults, there are a few publications of the most efficient treatment methods and subsequent patient outcomes<sup>4,5</sup> and pilocytic astrocytoma is associated with higher mortality in adult patients than in children and adolescents. In this review, we report the main characteristics of pilocytic astrocytomas for a better understanding of the diagnosis and treatment of these patients [7][8][13].

Pilocytic astrocytoma (PA) treated with complete or near complete tumor resection tends to have a better prognosis, recent studies recommend aggressive tumor resection without neurologic deficits. The prognosis for patients with pilocytic astrocytoma (PA) is generally good and the overall survival rate depends on the behavior of the tumor, its location, and the consequences of clinical manifestations, the age of the patient, and the treatment chosen. Overall survival in pediatric patients is about 90% at 10 years, whereas in adults older than 40 years this rate is close to 70% [13][14]

Pilocytic astrocytoma (PA) is a low-grade astrocytoma from the WHO classification in general. Low-grade astrocytomas have the potential to differentiate into high-grade astrocytomas. Sometimes unfortunate evolutions can occur. This feature is characterized by phenomena such as local recurrence, multicentric disease, leptomeningeal spread or malignant transformation [14].

Comparison MRI images of PNET, Craniopharyngioma and Pilocytic Astrocytoma : [5][7][8][10]

PNET	Craniopharyngioma	Pilocytic astrocytoma
<ul style="list-style-type: none"> <li>• <b>T1:</b> highly variable and can be hypointense to isointense</li> <li>• <b>T2</b> <ul style="list-style-type: none"> <li>○ generally high signal solid components</li> <li>○ cystic components are common</li> <li>○ low signal portions due to calcific components</li> </ul> </li> <li>• <b>T1 C+ (Gd)</b> <ul style="list-style-type: none"> <li>○ Shows markedly heterogeneous enhancement</li> <li>○ Leptomeningeal seeding is common</li> </ul> </li> <li>• <b>DWI:</b> often shows restricted diffusion</li> <li>• <b>MR spectroscopy</b> <ul style="list-style-type: none"> <li>○ elevated choline</li> <li>○ decreased NAA elevated taurine (Tau) peak (relatively specific for PNET)</li> </ul> </li> </ul>	<ul style="list-style-type: none"> <li>• cysts           <ul style="list-style-type: none"> <li>○ <b>T1:</b> iso- to hyperintense to grey matter <sup>11</sup> (due to high protein content "motor oil cysts")</li> <li>○ <b>T2:</b> variable but ~80% are mostly or partly T2 hyperintense</li> </ul> </li> <li>• solid component           <ul style="list-style-type: none"> <li>○ <b>T1 C+ (Gd):</b> vivid enhancement</li> <li>○ <b>T2:</b> variable or mixed</li> </ul> </li> <li>• calcification           <ul style="list-style-type: none"> <li>○ Difficult to appreciate on conventional imaging</li> <li>○ Susceptible sequences may better demonstrate calcification</li> </ul> </li> <li>• <b>MR angiography:</b> may show displacement of the A1 segment of the anterior cerebral artery</li> <li>• <b>MR spectroscopy:</b> cyst contents may show a broad lipid</li> </ul>	<ul style="list-style-type: none"> <li>• <b>T1:</b> <ul style="list-style-type: none"> <li>○ solid component: iso to hypointense compared to adjacent brain</li> <li>○ cystic component: ~fluid signal unless hemorrhage</li> </ul> </li> <li>• <b>T1 C+ (Gd):</b> <ul style="list-style-type: none"> <li>○ vivid contrast enhancement</li> <li>○ the cyst wall enhances in ~50% cases</li> </ul> </li> <li>• <b>T2:</b> <ul style="list-style-type: none"> <li>○ solid component: hyperintense compared to adjacent brain</li> <li>○ cystic component: high signal</li> </ul> </li> <li>• <b>T2*/GRE/SWI:</b> <ul style="list-style-type: none"> <li>○ signal loss if calcification or</li> </ul> </li> </ul>

	spectrum, with an otherwise flat baseline	hemorrhage present
--	---	--------------------

### Conclusion

Pilocytic astrocytoma (PA) treated with complete or near complete tumor resection tends to have a better prognosis, recent studies recommend aggressive tumor resection without neurologic deficits. The prognosis for patients with pilocytic astrocytoma (PA) is generally good and the overall survival rate depends on the behavior of the tumor, its location, and the consequences of clinical manifestations, the age of the patient, and the treatment chosen. Overall survival in pediatric patients is about 90% at 10 years, whereas in adults older than 40 years this rate is close to 70%.

Pilocytic astrocytoma (PA) is a low-grade astrocytoma from the WHO classification in general. Low-grade astrocytomas have the potential to differentiate into high-grade astrocytomas. Sometimes unfortunate evolutions can occur. This feature is characterized by phenomena such as local recurrence, multicentric disease, leptomeningeal spread or malignant transformation (MT).



## References :

- [1]. Richterova R, Kolarovszki B. Primary brain tumors in childhood. Intechopen. 2018
- [2]. Kang JM, Ha J, Hong EK, Ju HY, Park BK, Shin SH, Won YJ, Jung KW, Park HJ. A Nationwide, population-based epidemiologic study of childhood brain tumors in Korea, 2005- 2014: A comparison with United States data. *Cancer Epidemiol Biomarkers Prev.* 2019 Feb;28(2):409-416. doi: 10.1158/1055-9965.EPI-18-0634.
- [3]. Butowski, N. 2012. Management of The Tumor Patient. *In: Imaging og the Brain.* Saunders Elsevier, Philadelphia. Chapter 38. hlm. 440.
- [4]. Ellenbogen, R.G., Abdulrauf, S.I. and Sekhar, L.N. 2012. *Low-grade and Highgrade Glioma.* *In: Principles of Neurological Surgery.* Ed ke3. Elsevier, Philadelphia. Chapter 34. hlm. 527.
- [5]. Ferri, F.F. 2009. Brain Neoplasms. *In: Ferri's Color Atlas and Text of Clinical Medicine.* Chapter 38. Saunders Elsevier, Philadelphi. hlm. 186.
- [6]. Forsyth P.A., Swah E.G., Scheithauer B.W., O'Fallon J.R., Layton D.D. et al. 1993. Supratentorial plocytic astrocytoma. *Cancer.* hlm. 1335-1342.
- [7]. Hanson, D.H. and Atlas, M.P. 2016. Central Nervous System Malignancies. *In: Lanzkowsky's Manual of Pediatric Hematology and Oncology.* Chapter 23. Elsevier, Philadelphia. hlm. 461
- [8]. Inez, M.M., Bisri, D.Y. dan Adam, A. 2015. Insidensi Tumor Supratentorial berdasarkan Jenis dan Letaknya di RSUP Dr. Hasan Sadikin Tahun 2012-2013. *Jurnal Neuroanestesia Indonesia*
- [9]. Kieran, M.W., Chi, S.N., Manley, P.E., Green, A.L., Bandopadhyay, P. et al. 2015. Nathan and Oski's Hematology and Oncology of Infancy and Childhoo. *In: Tumors of The Brain and Spinal Cord.* Ed ke8. Saunders Elsevier: Philadelphia. hlm. 1816
- [10]. National Organization for Rare Disorders. 2015. Astrocytoma. <https://rarediseases.org/rare-diseases/astrocytoma/>. [27 Auguts 2018].
- [11]. Ostrom, Q.T., Gittleman, H., Liao, P., Rouse, C., Yan, W.C. et.al. 2014. CBTRUS statistical Report: Primary Brain and Central Nervous System Tumors Diagnosed in the United States in 2007-2011. *Neuro Oncol.*
- [12]. [UU RI] Undang-undang Republik Indonesia Nomor 23. 2002. Undang-Undang Republik Indonesia Nomor 23 Tahun 2002 tentang perlindungan anak.
- [13]. Winn, H.R. 2017. *Low-grade Glioma.* *In: Youmans & Winn Neurological Surgery.* Ed ke7. Elsevier, New York. hlm. 4396.
- [14]. Zhao, W. Schachner, M. 2013. Neureguline-1 Enhances Cell Adhesion Molecule L1 Expression in Human Glioma Cells and Promote Their Migration as A Function of Malignancy. *J Neuropathol Exp Neural.* American Association of Neuropathologist.